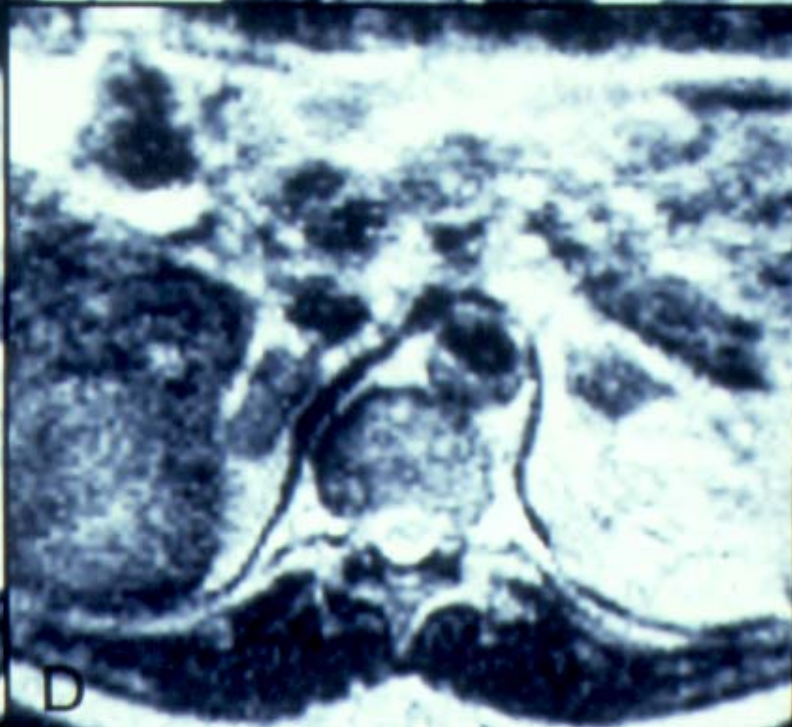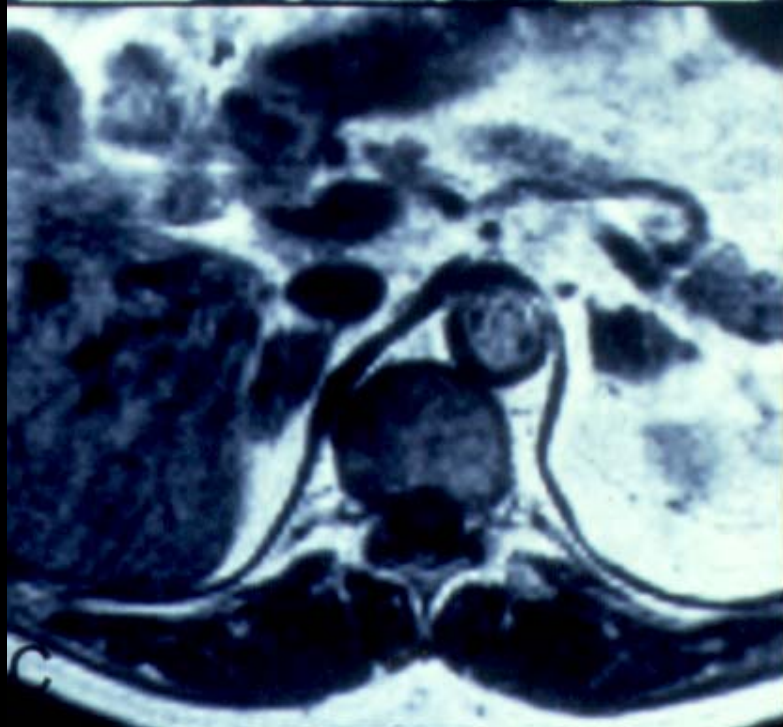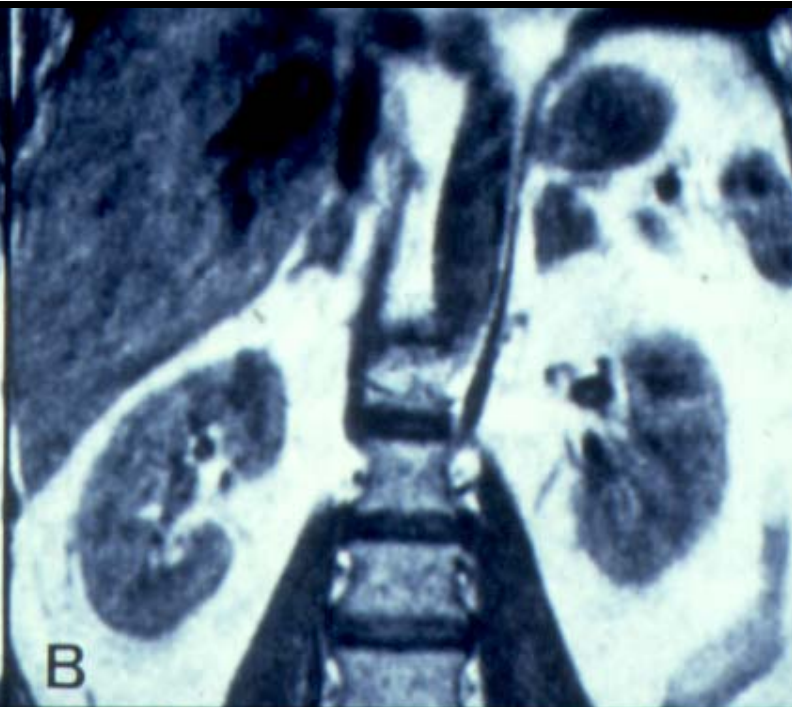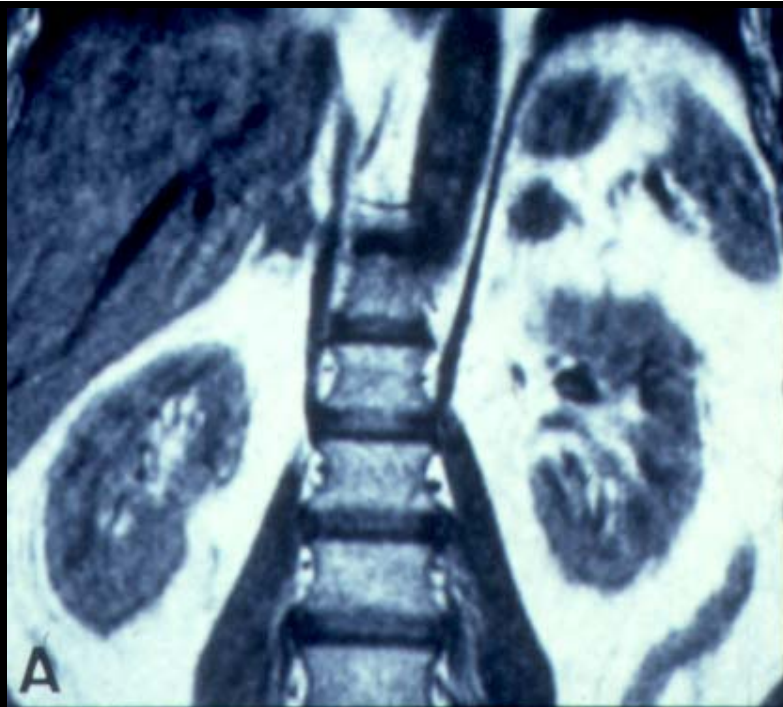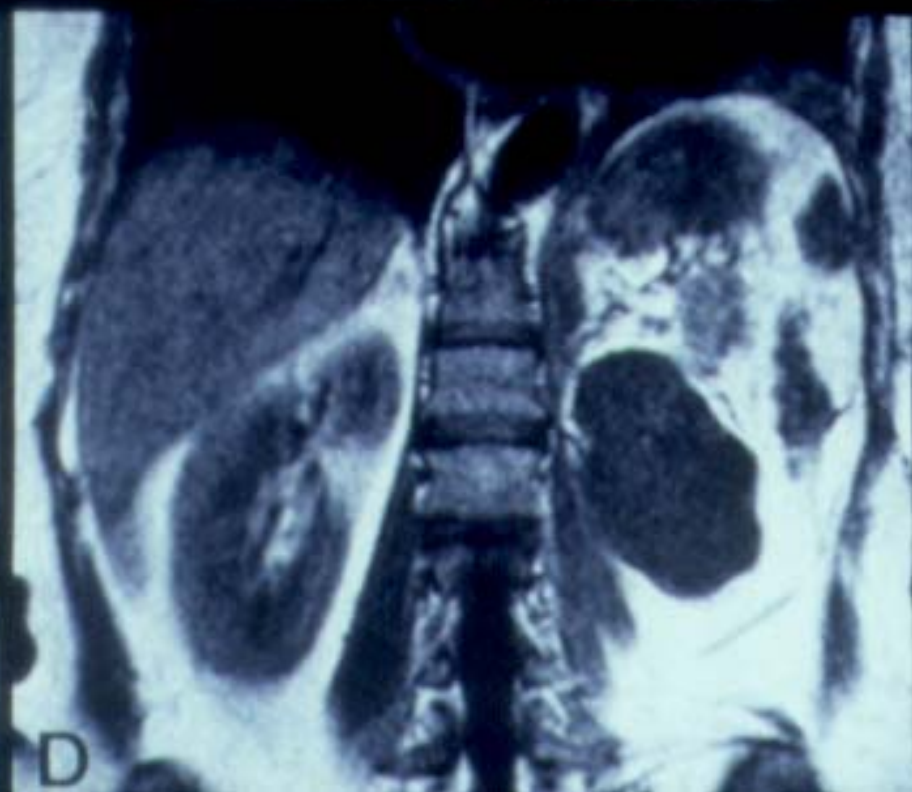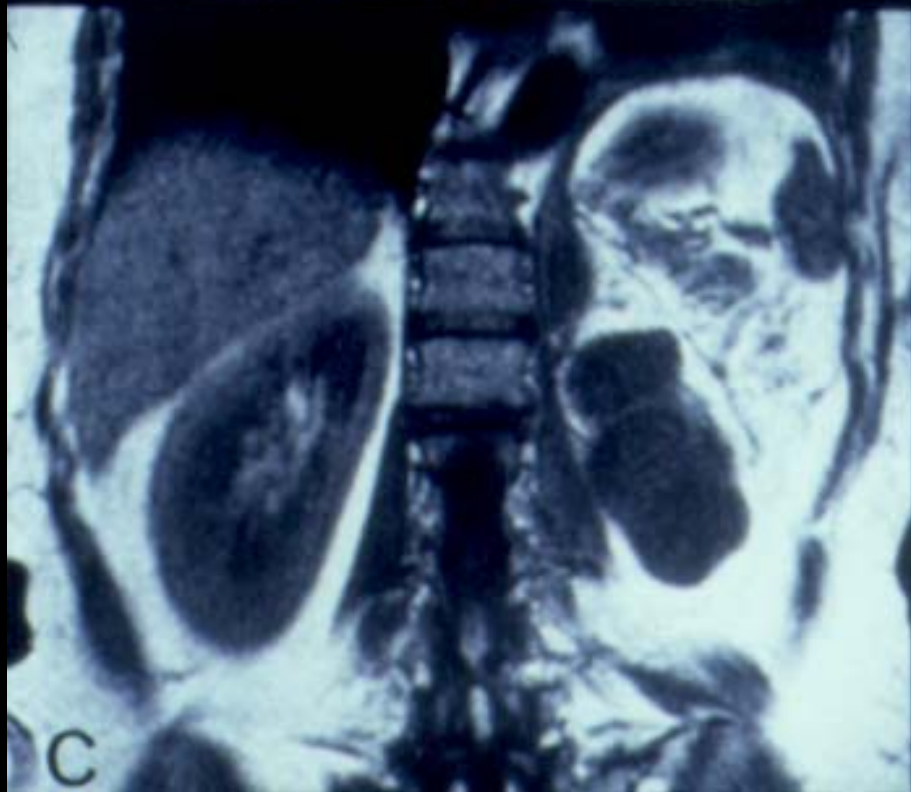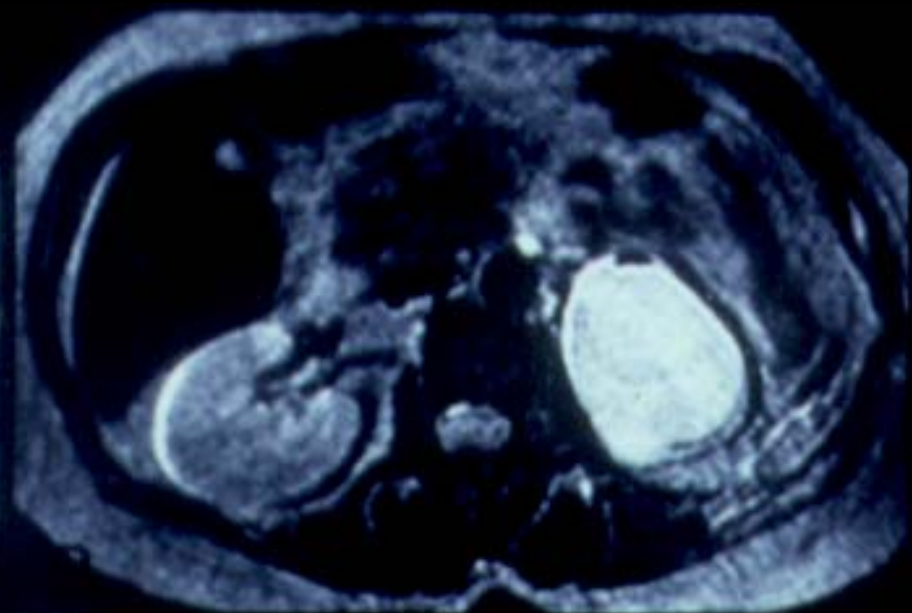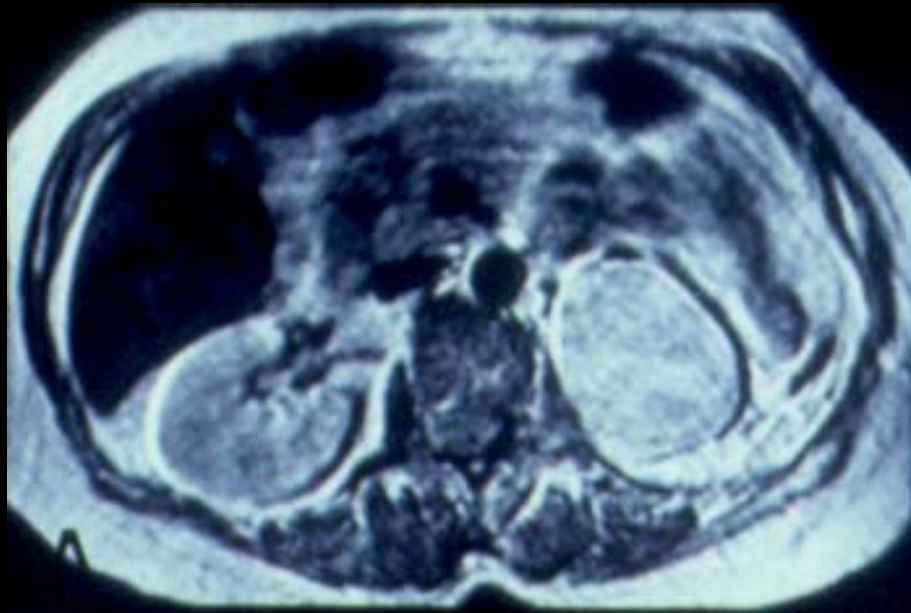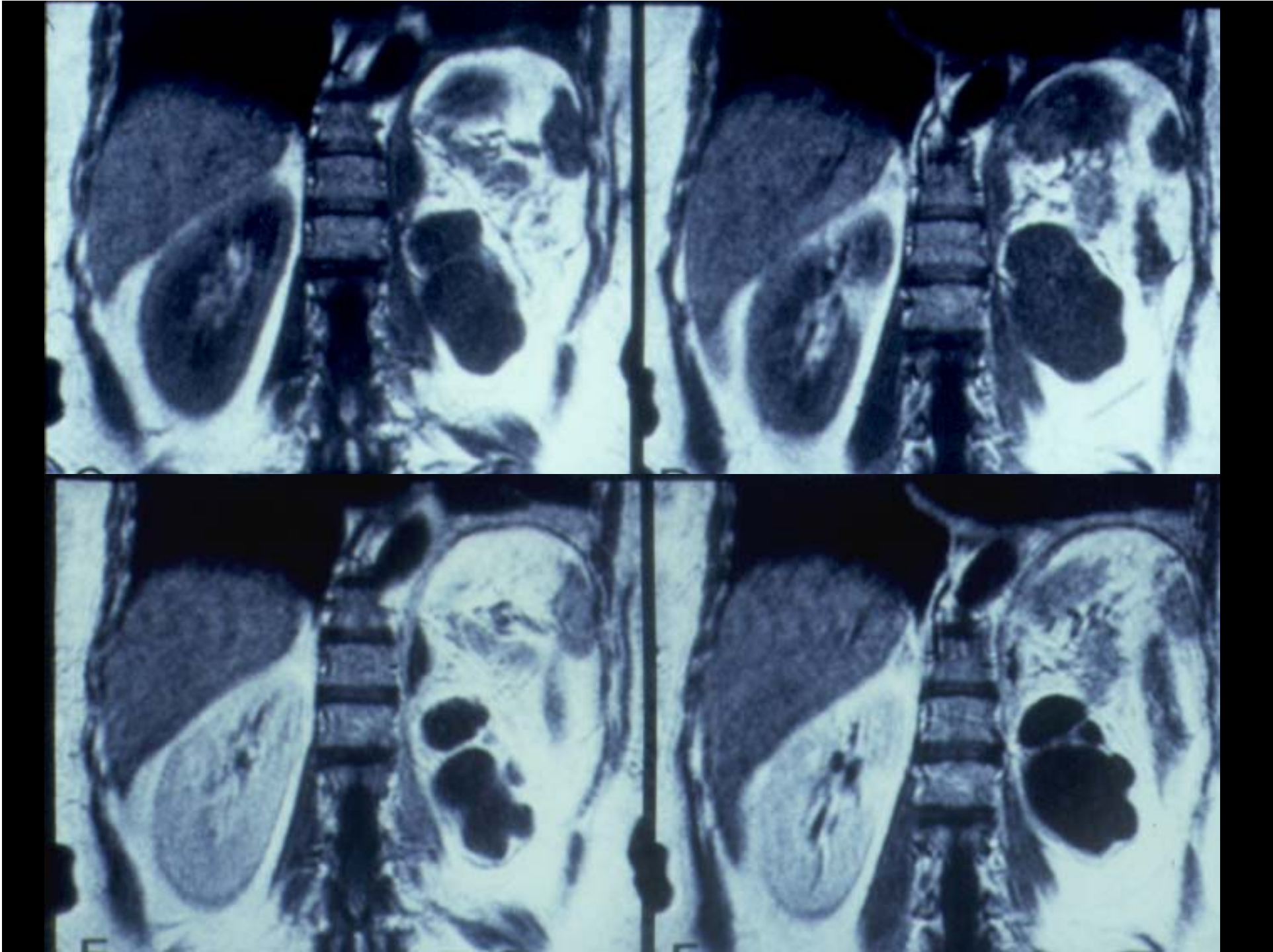
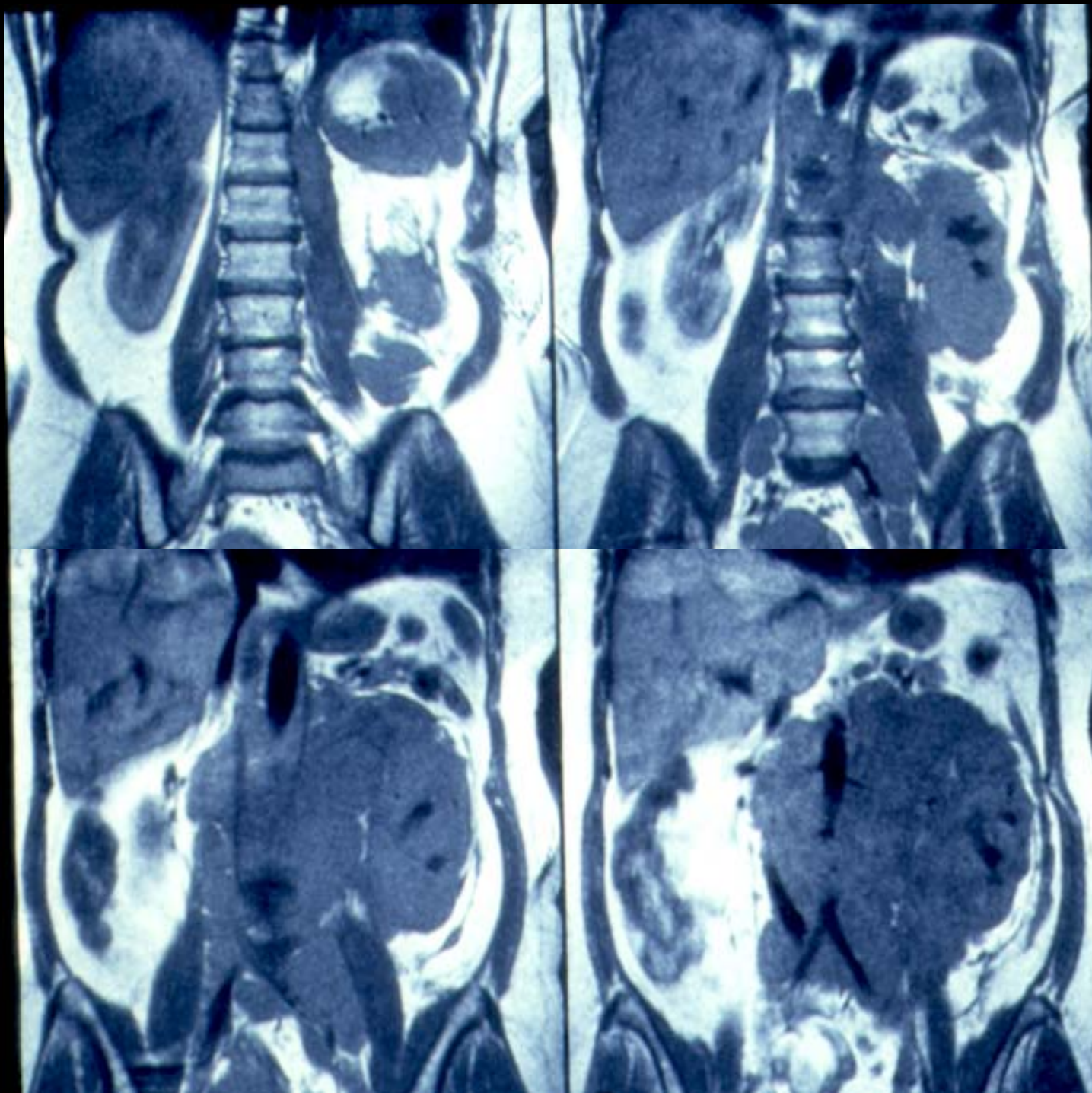
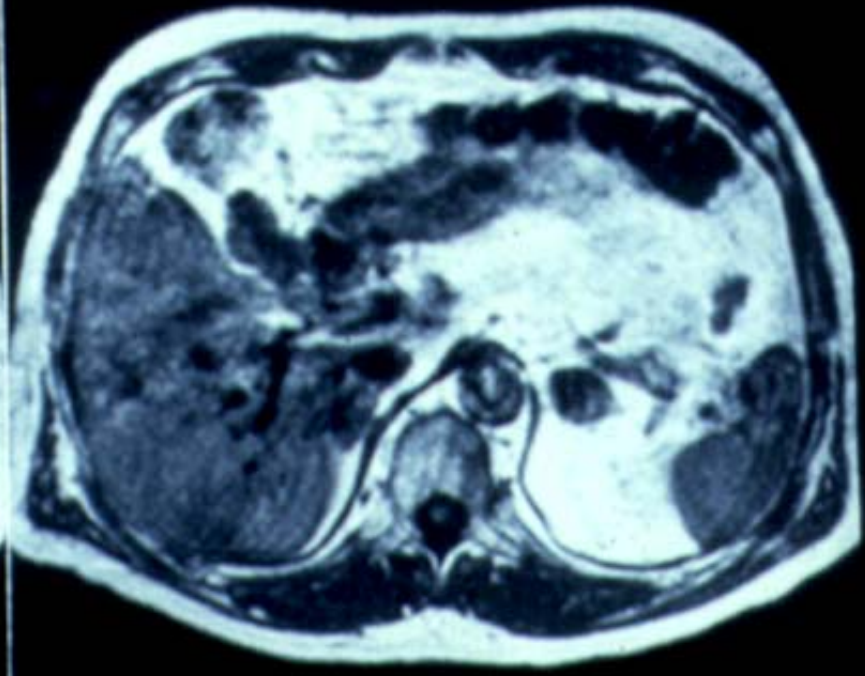
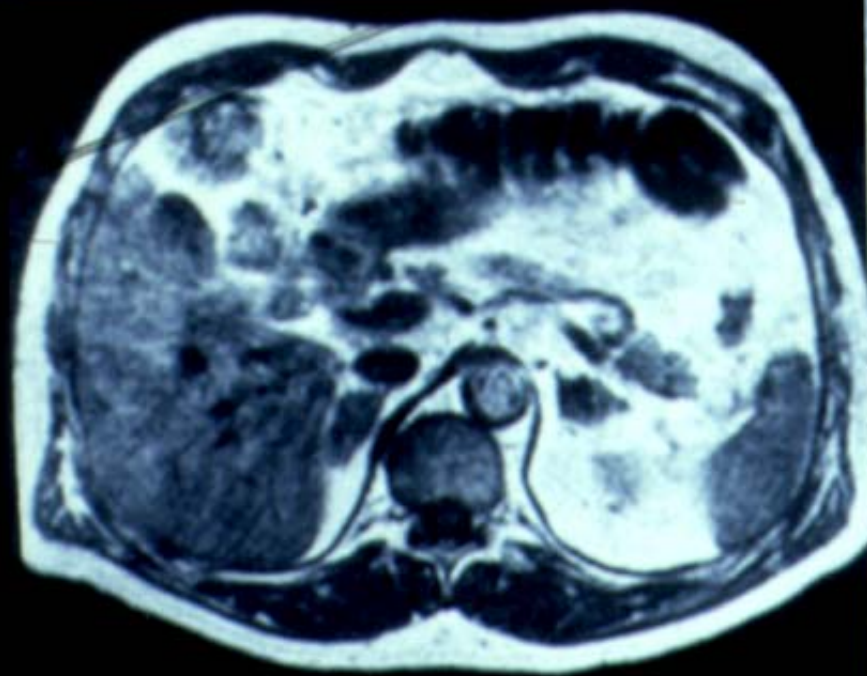
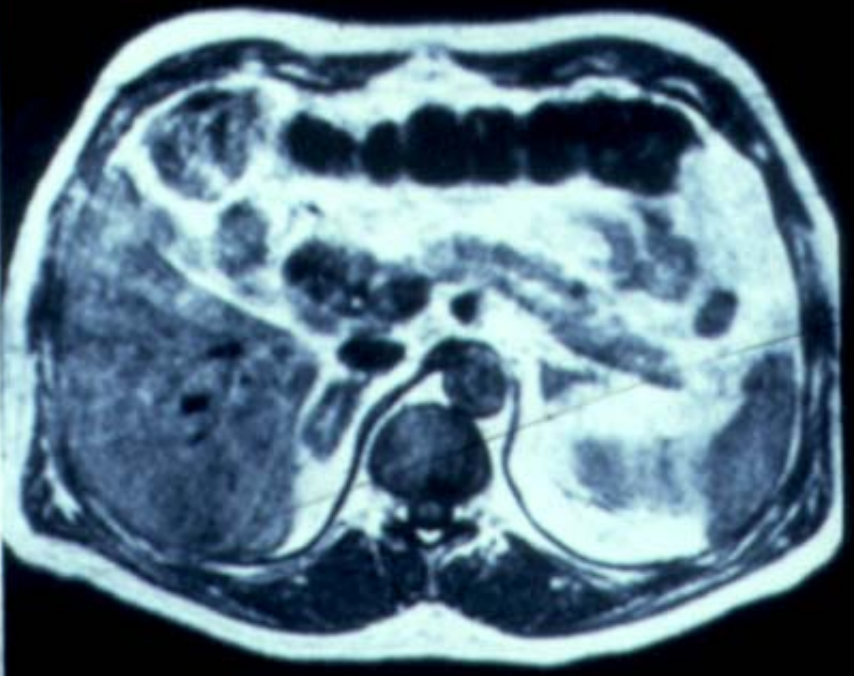
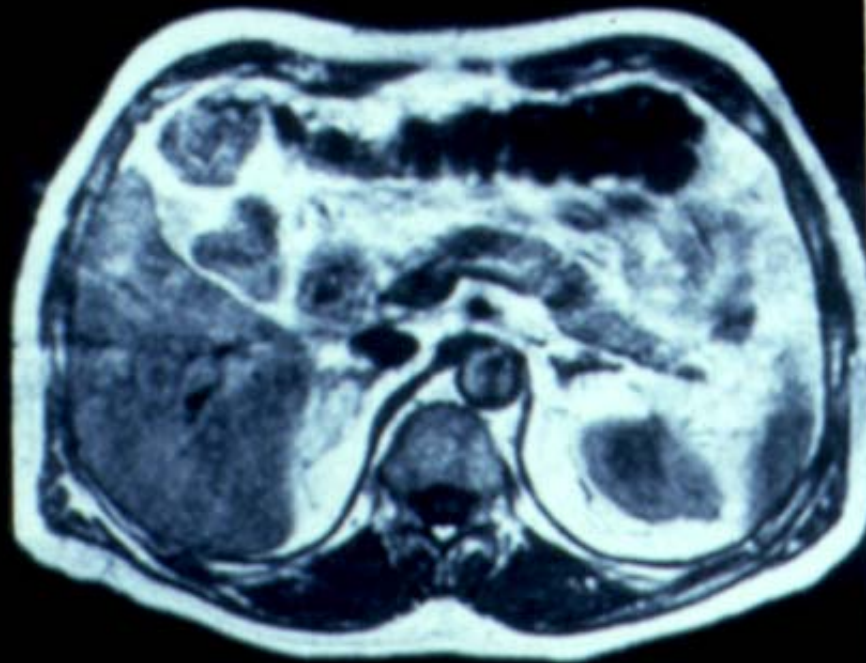


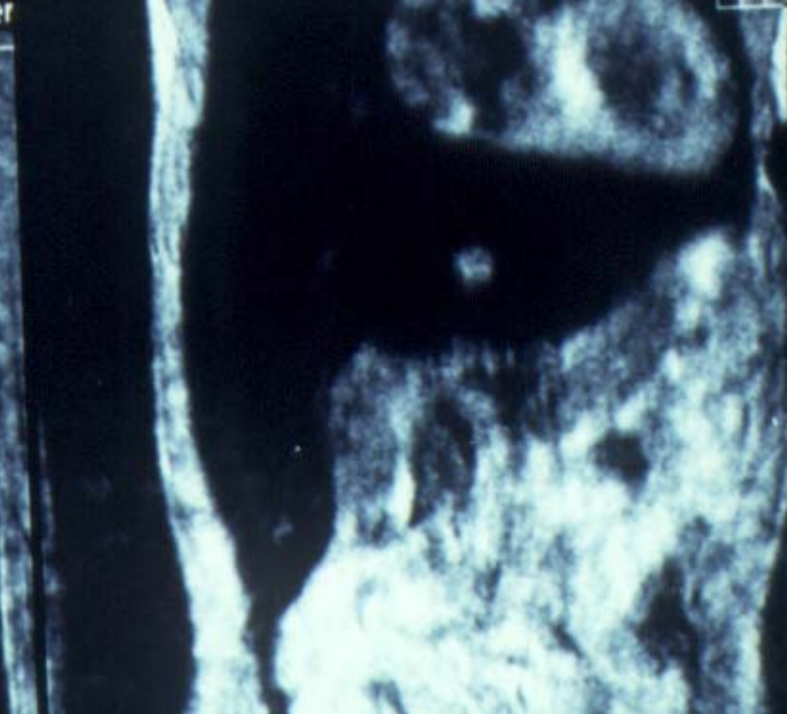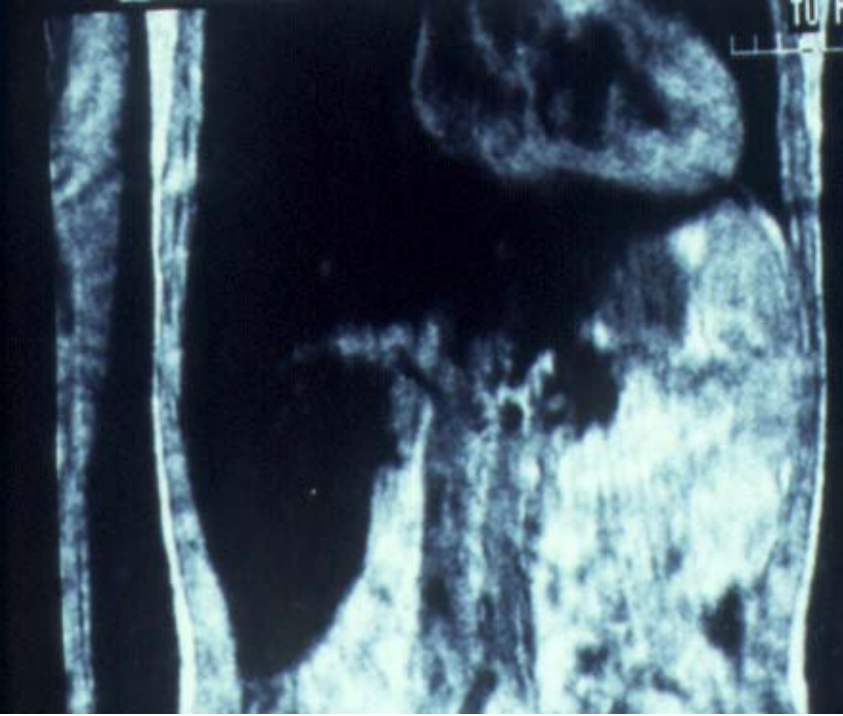
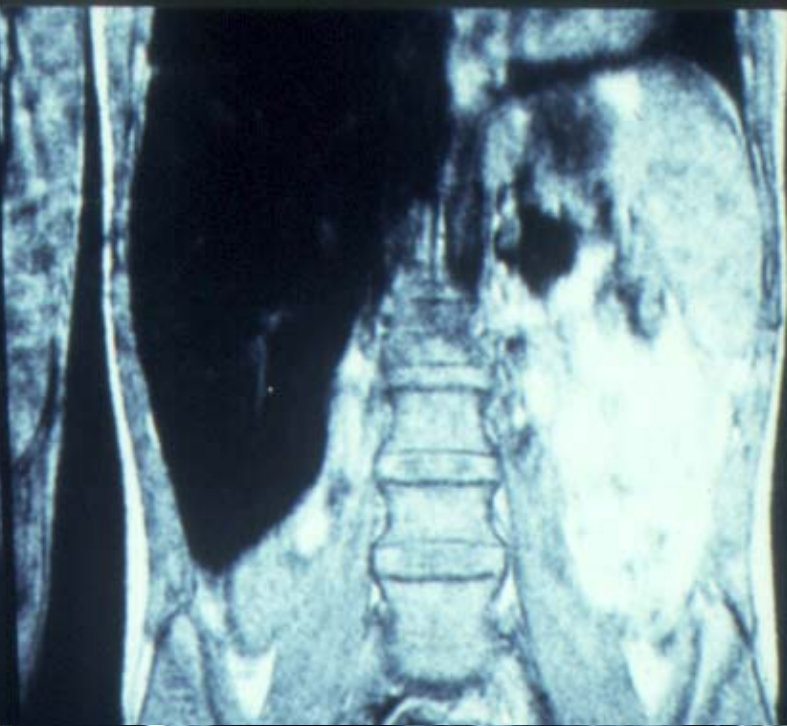
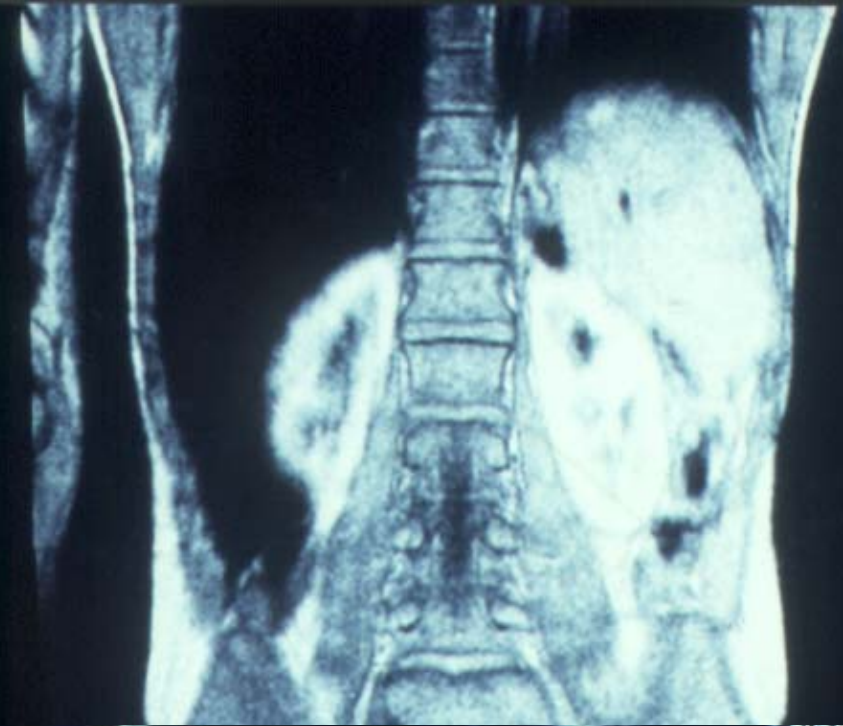C

D

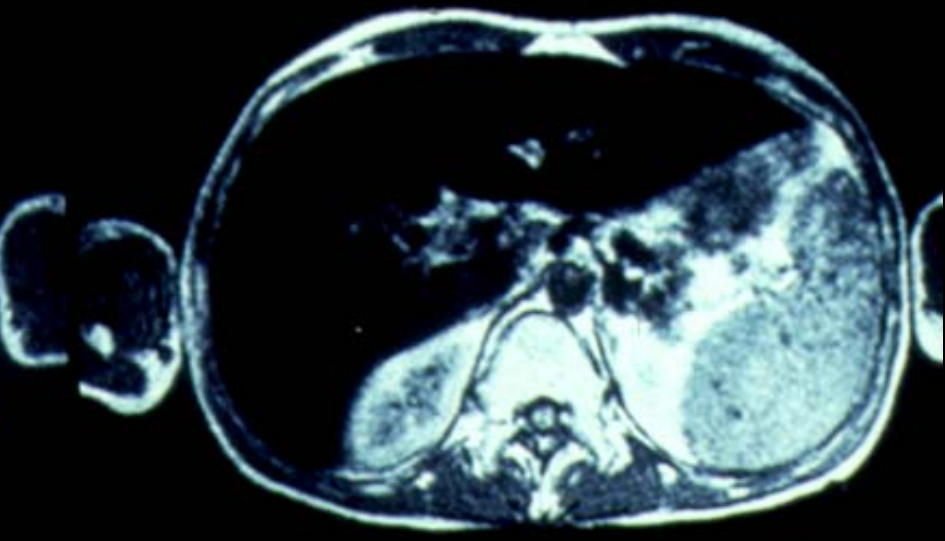
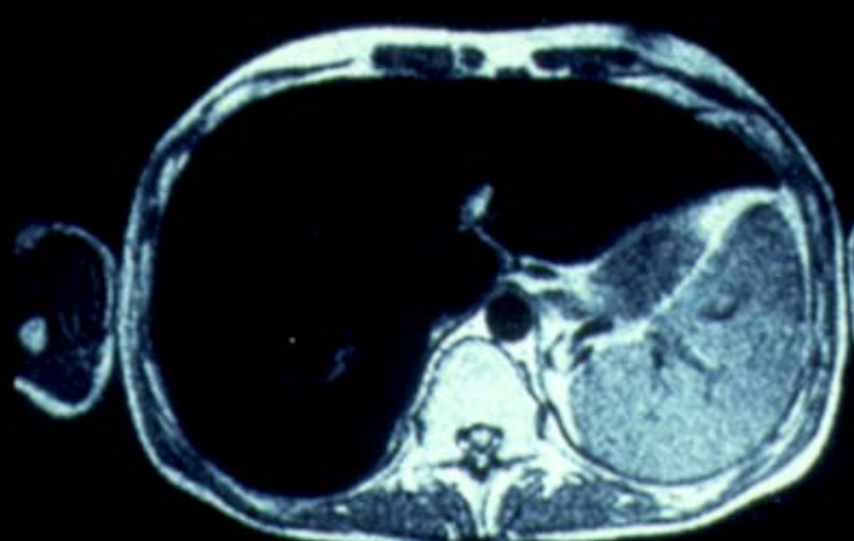
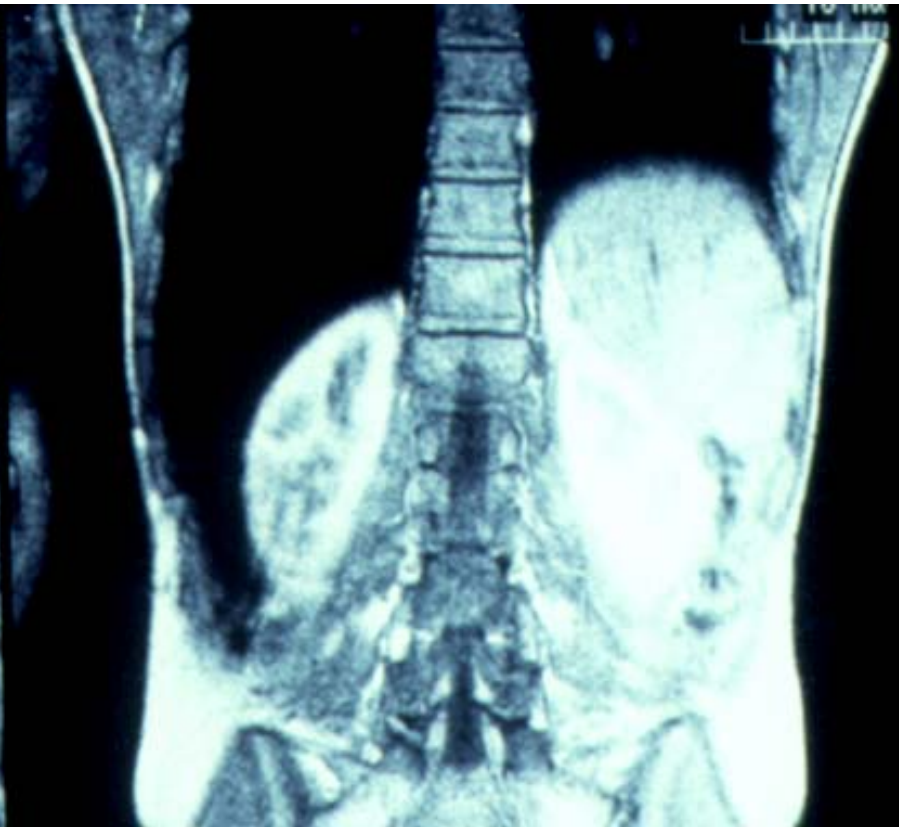
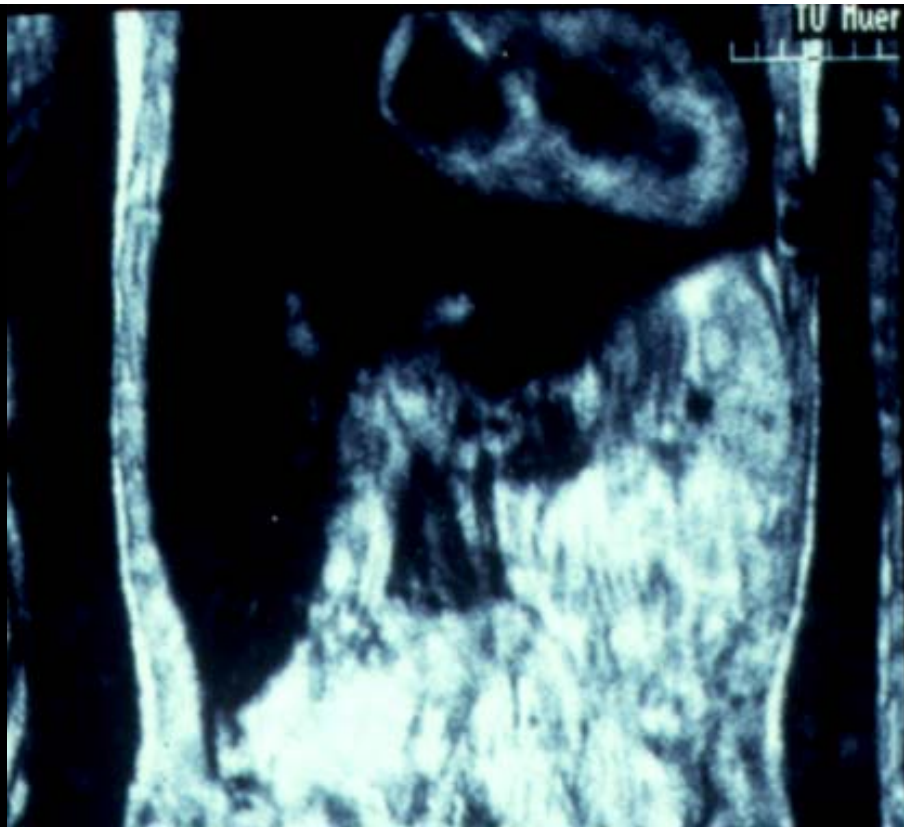
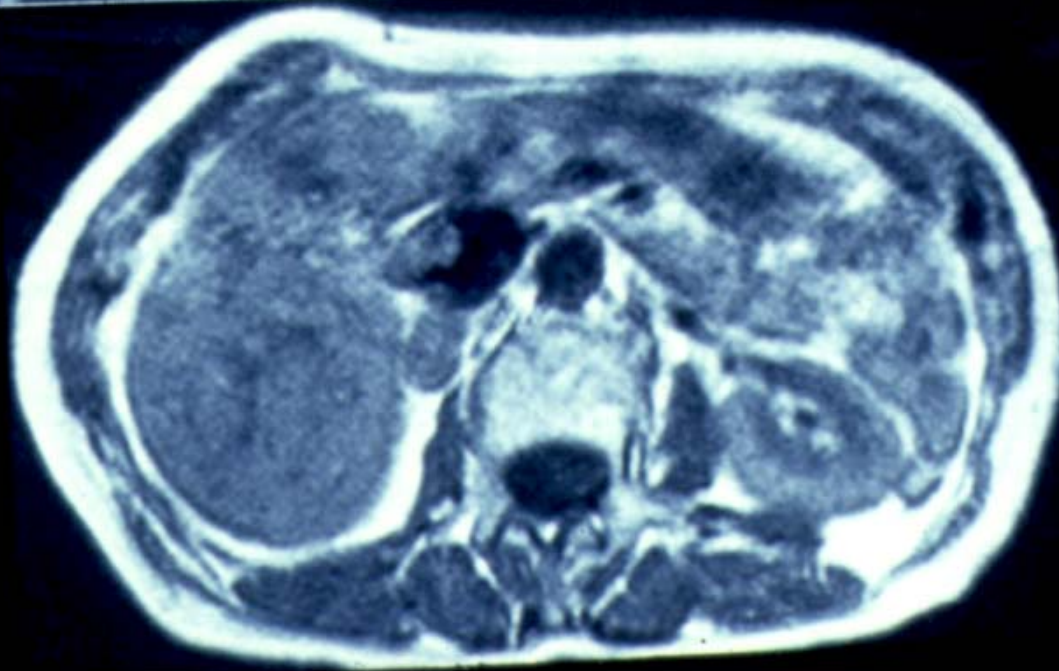
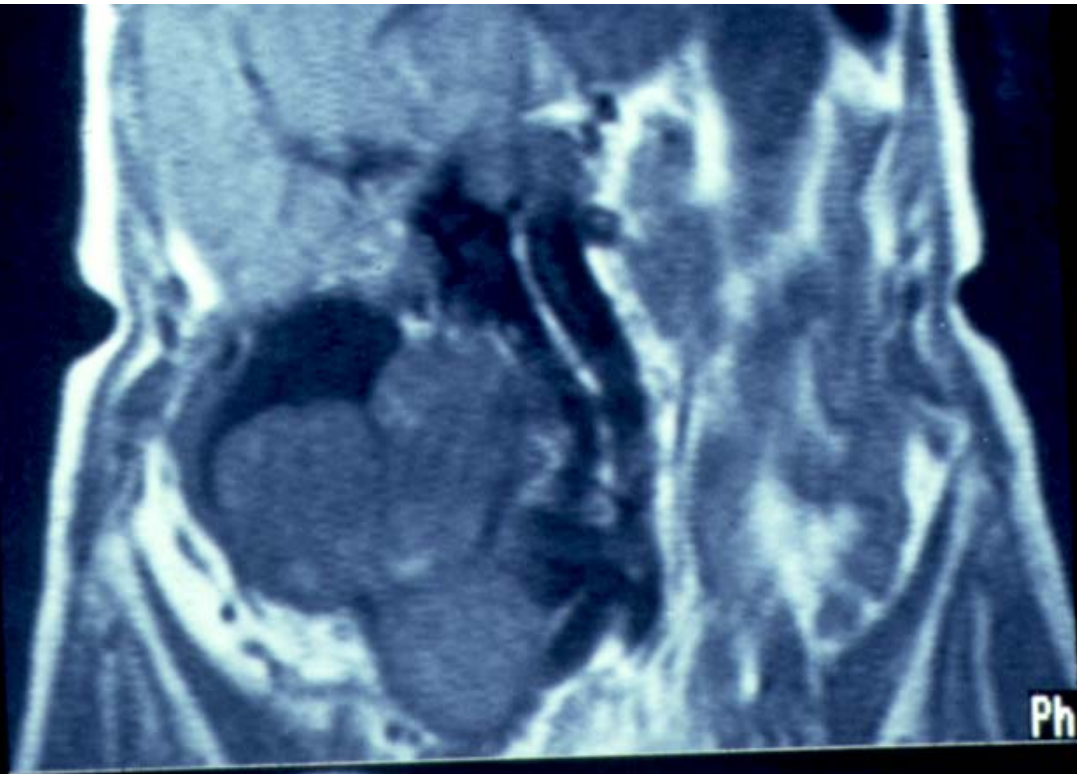




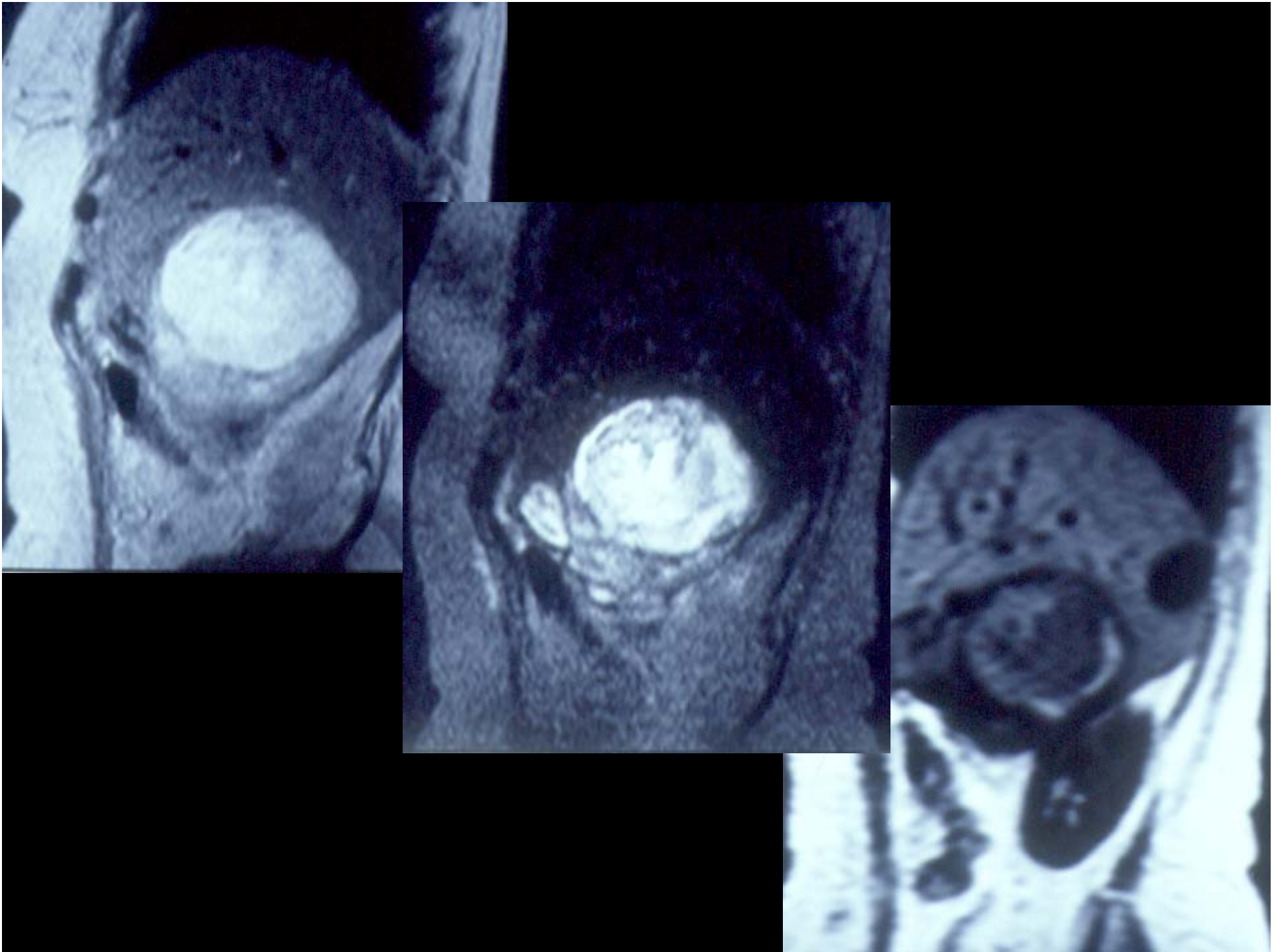


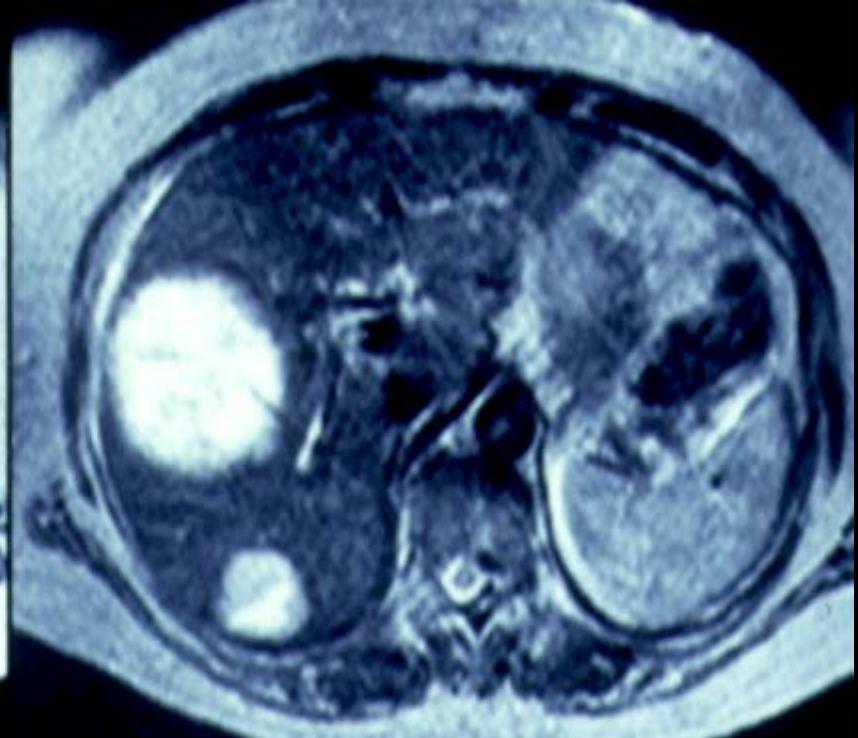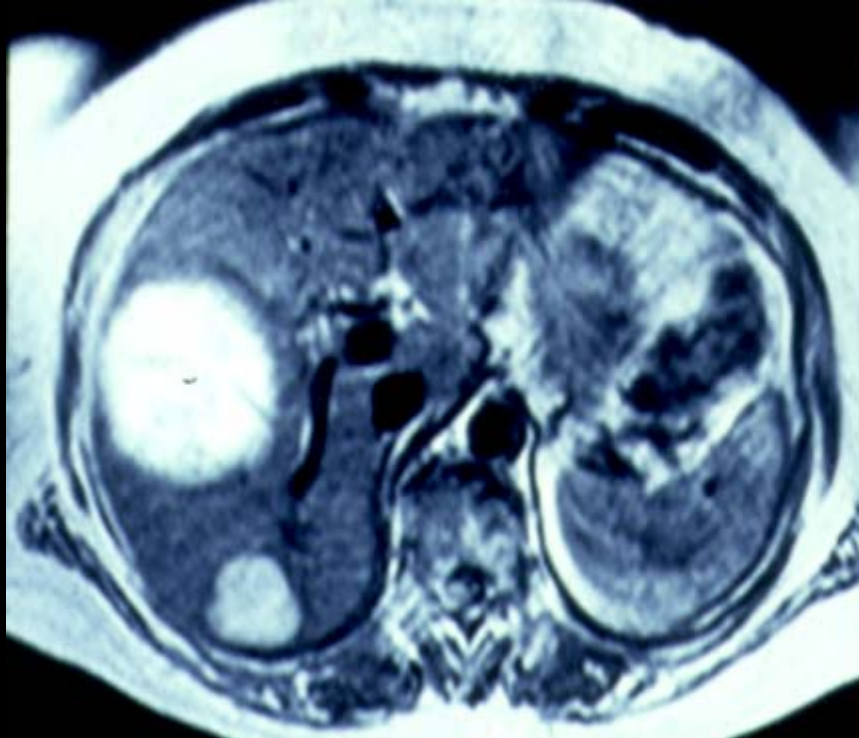
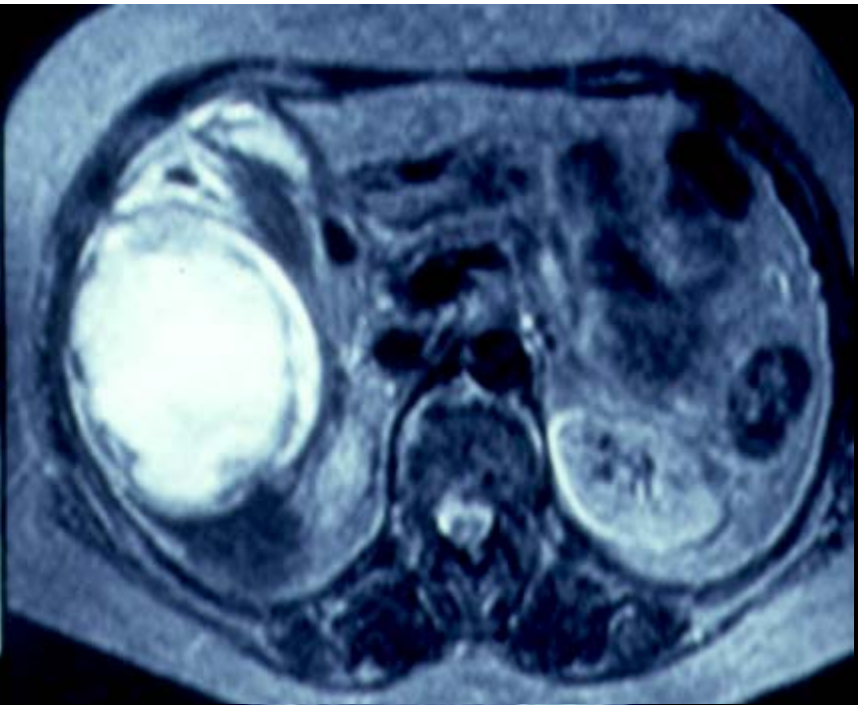
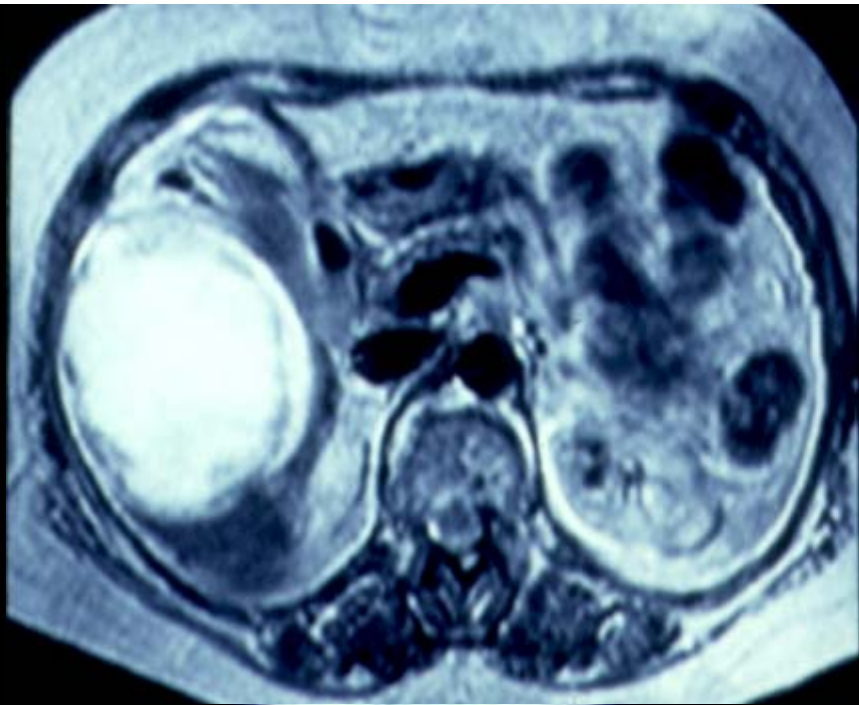
TU nuer  
1 2 3 4 5 6 7 8 9 10 11 12

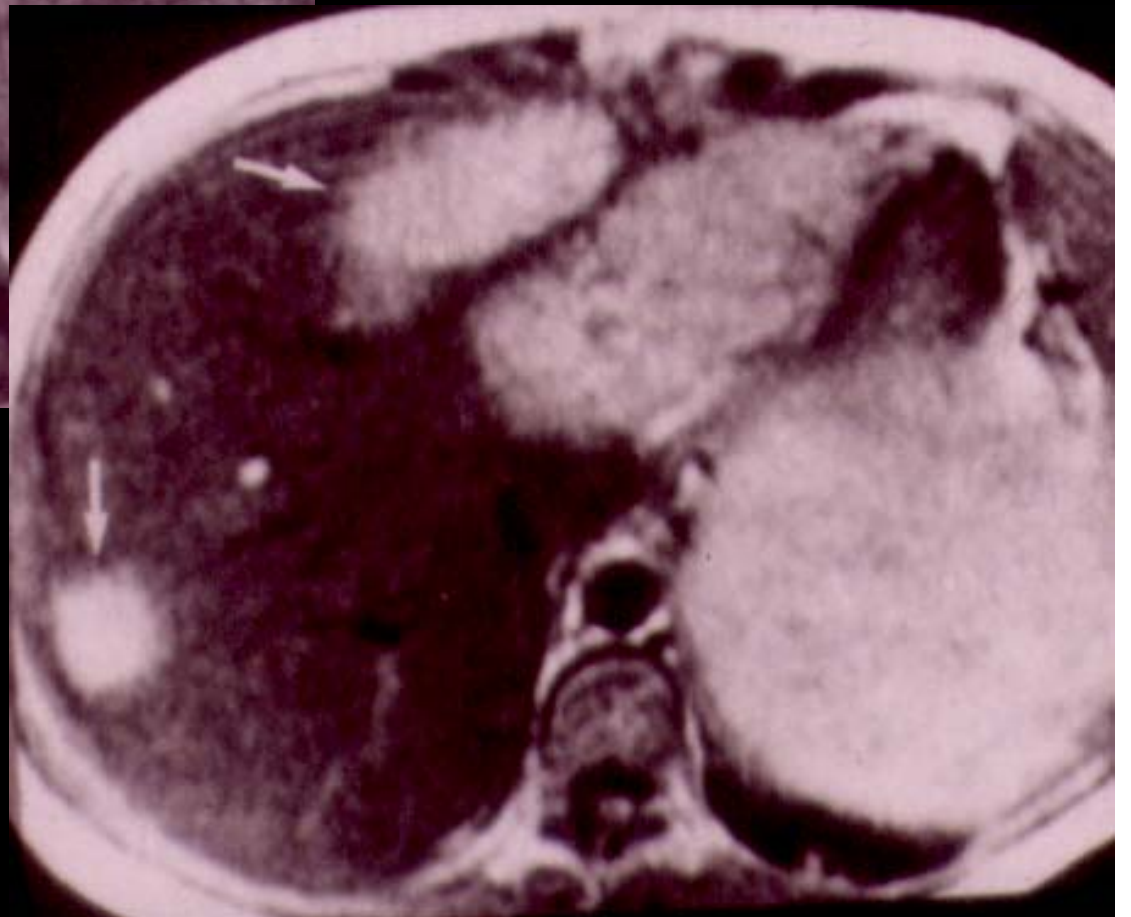
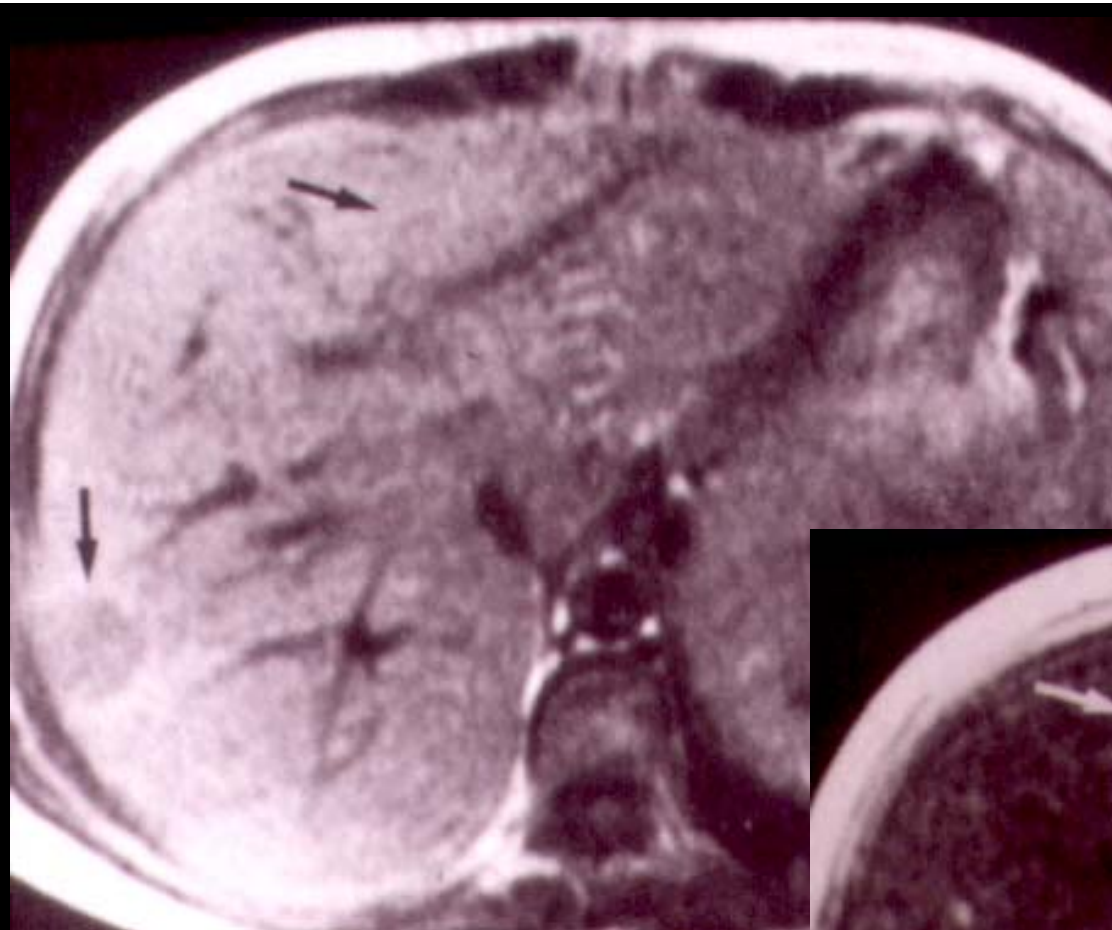


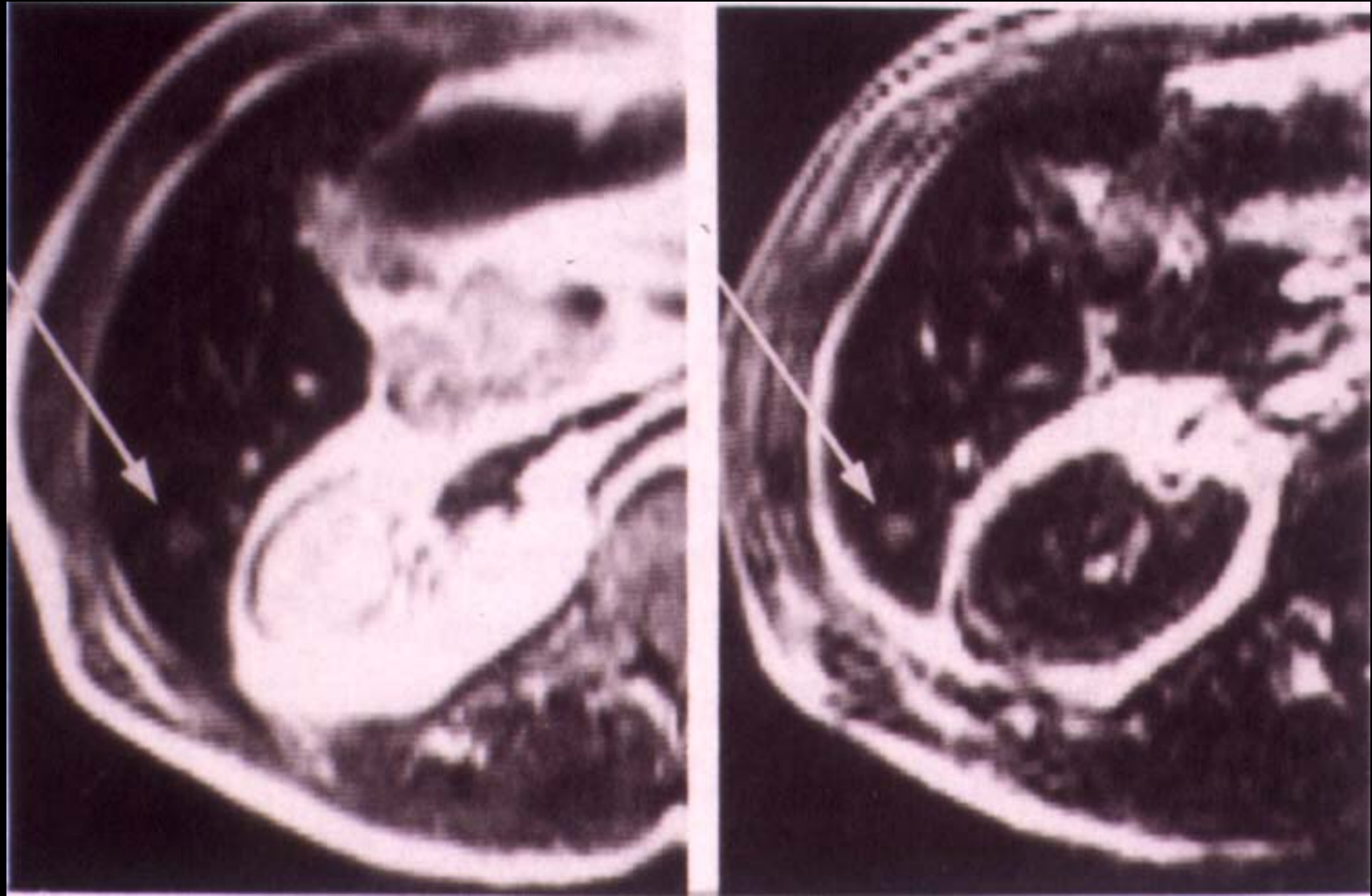












Stark: Radiology (1988)168:297

