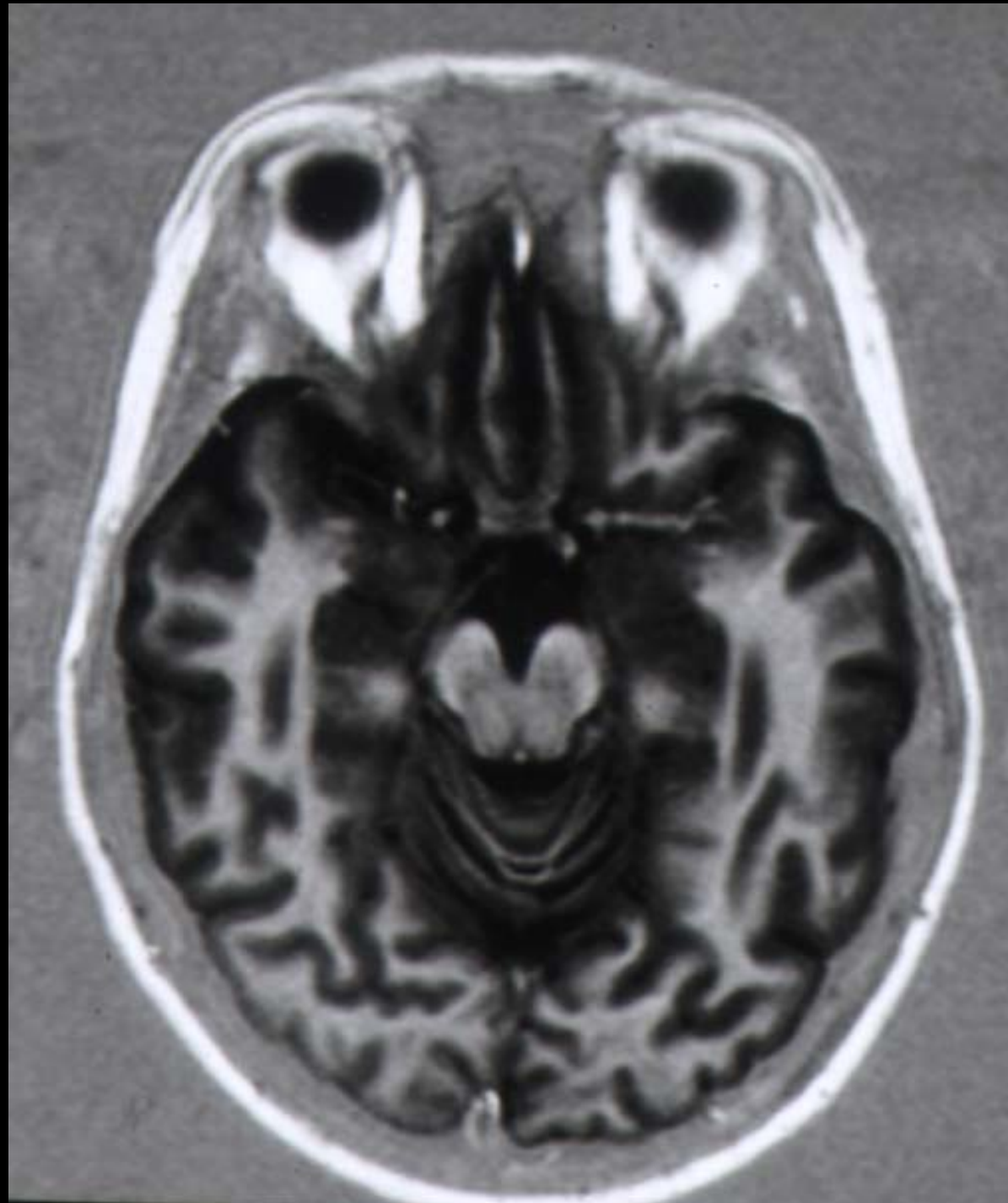
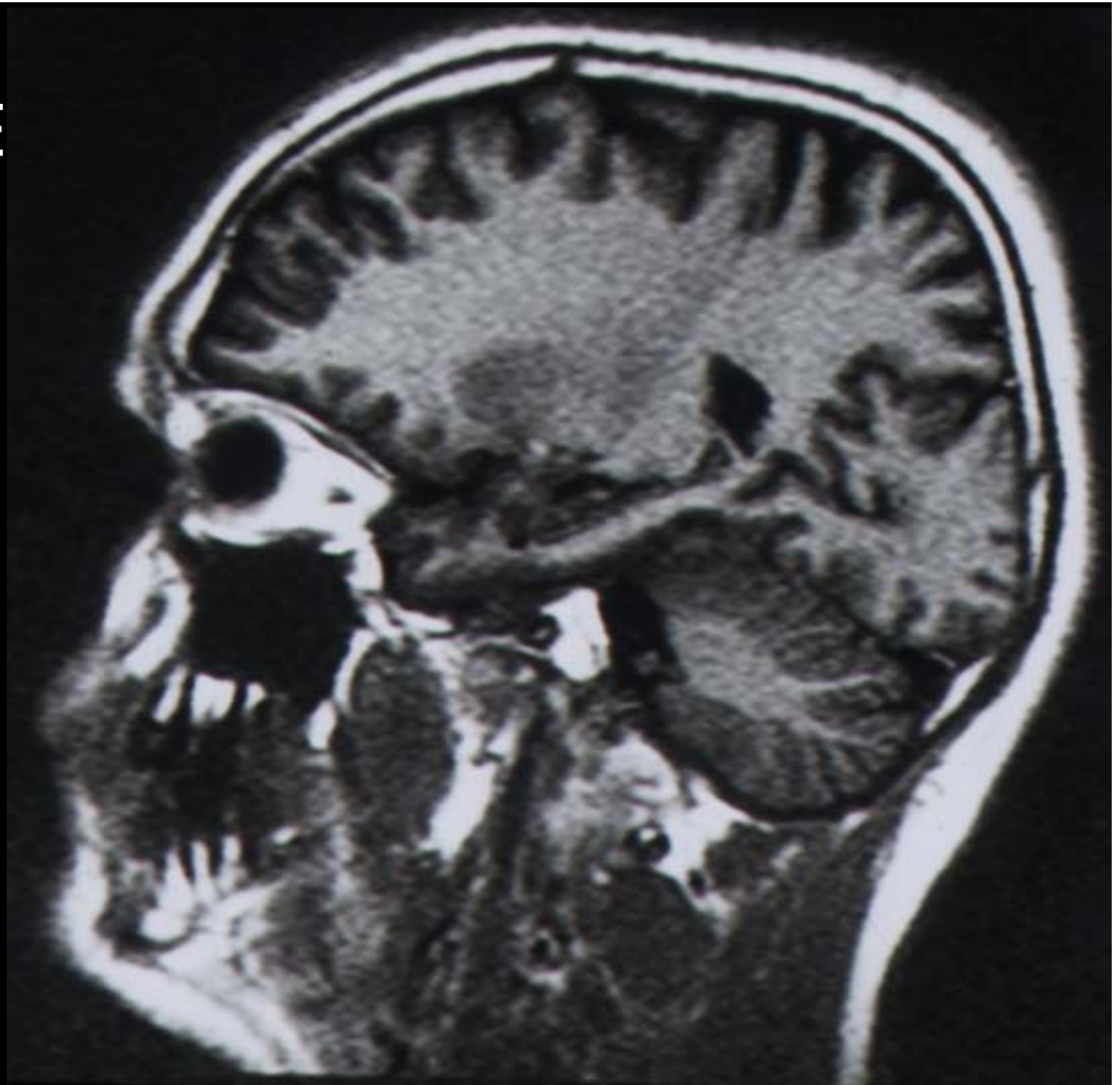


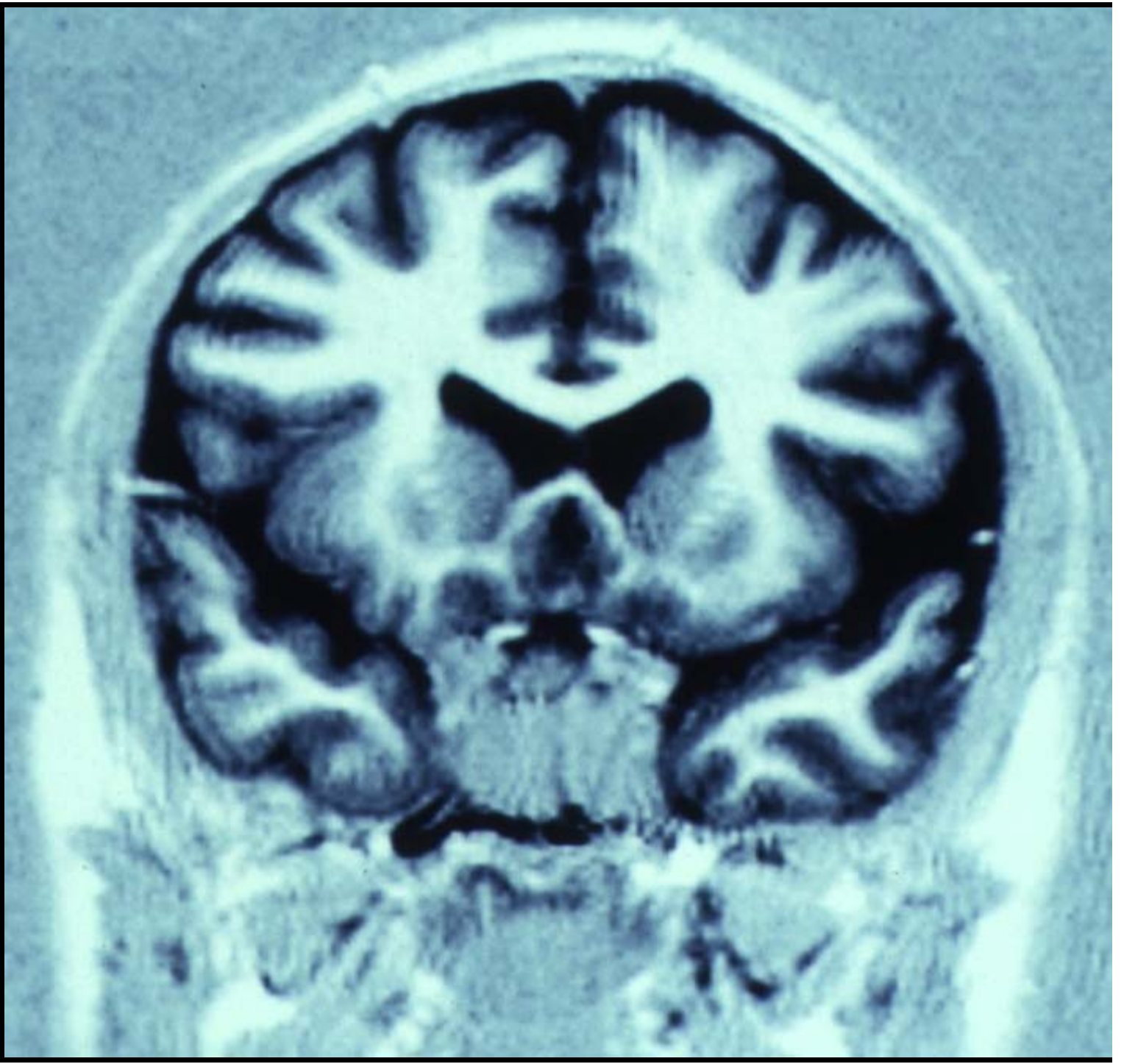
transversal
IE



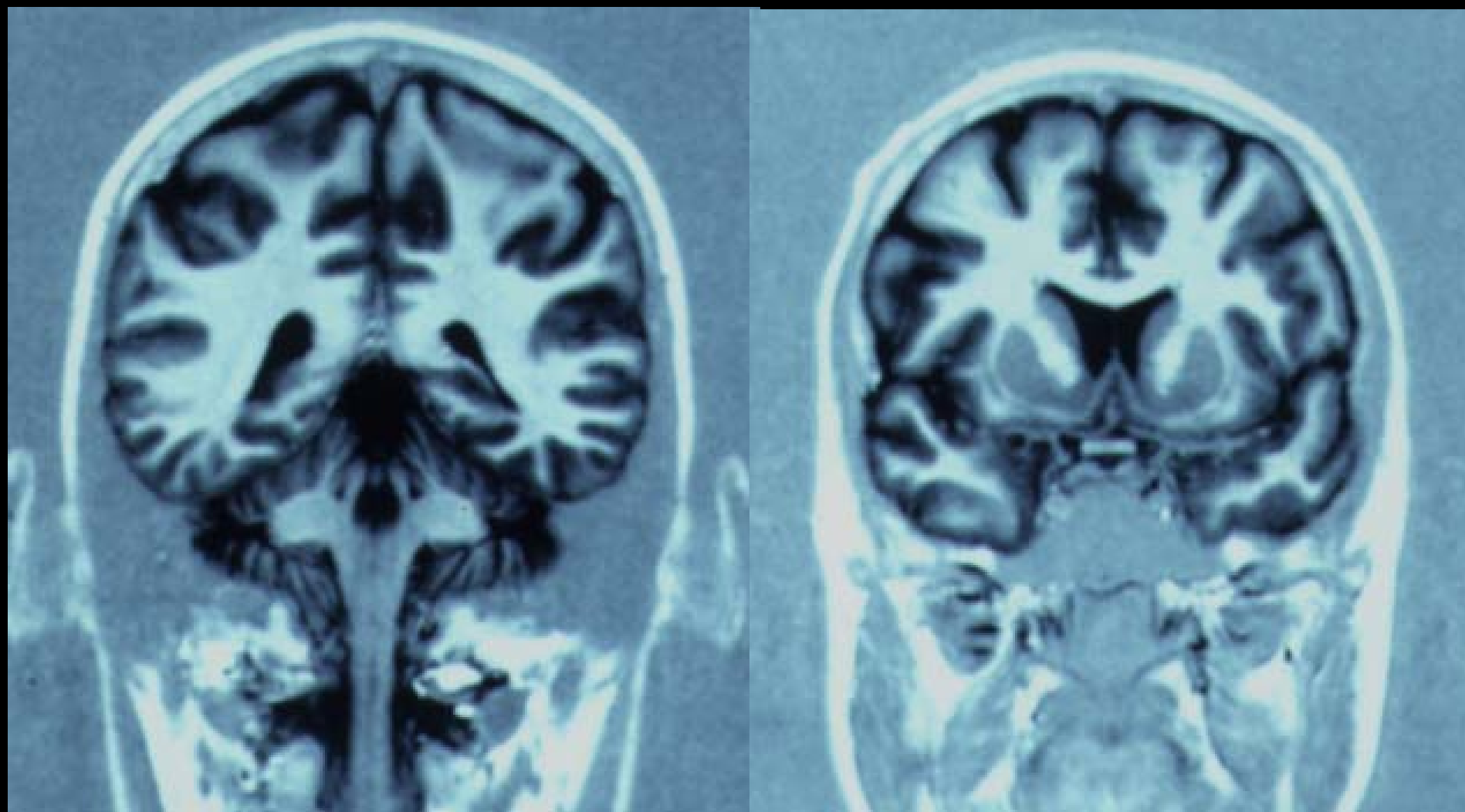
sagittal IE

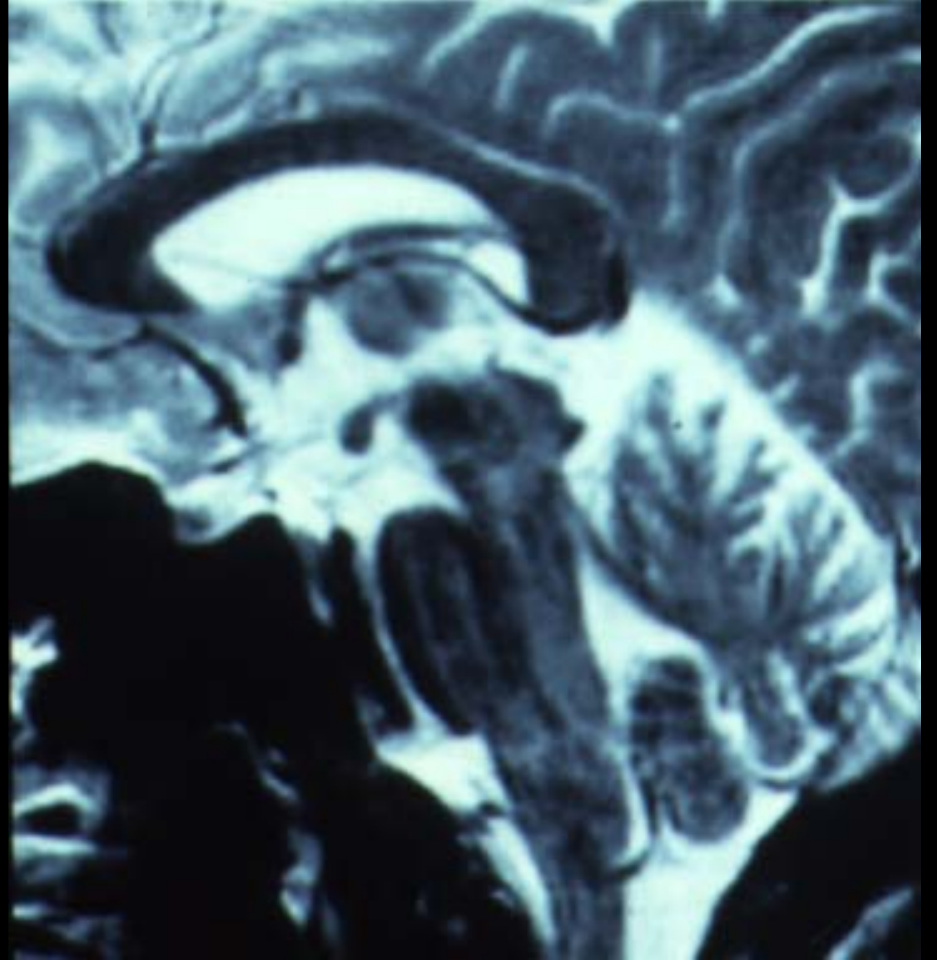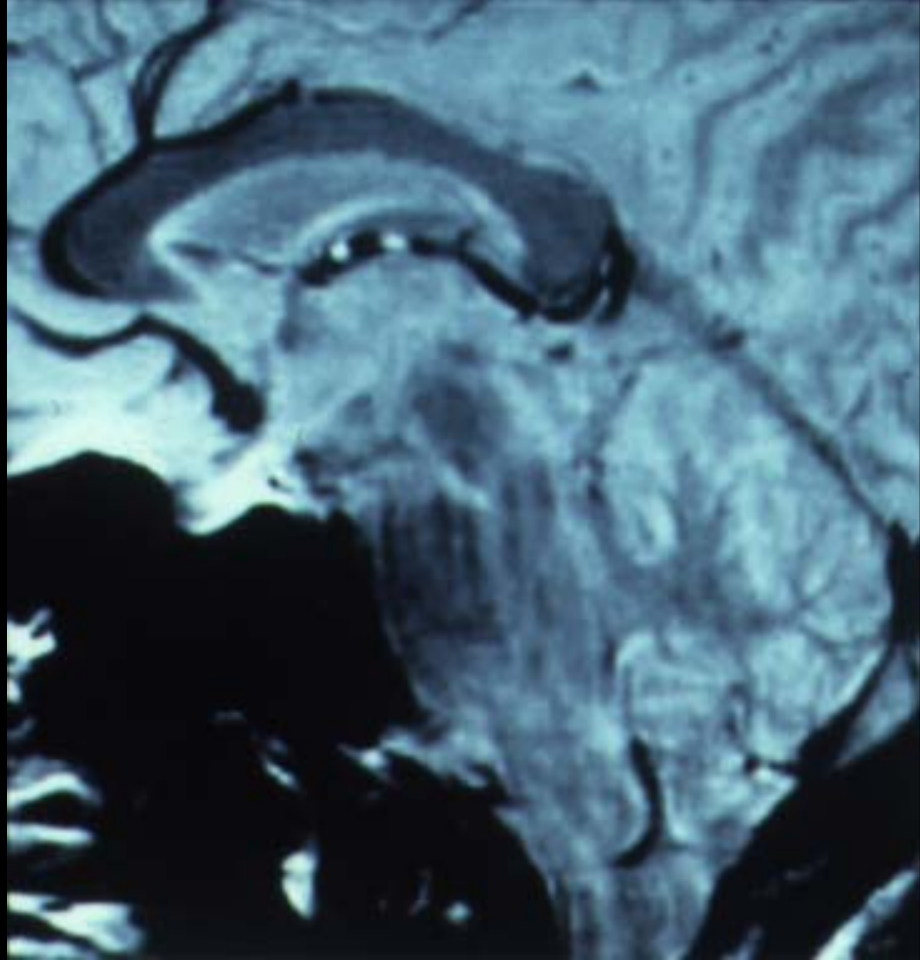


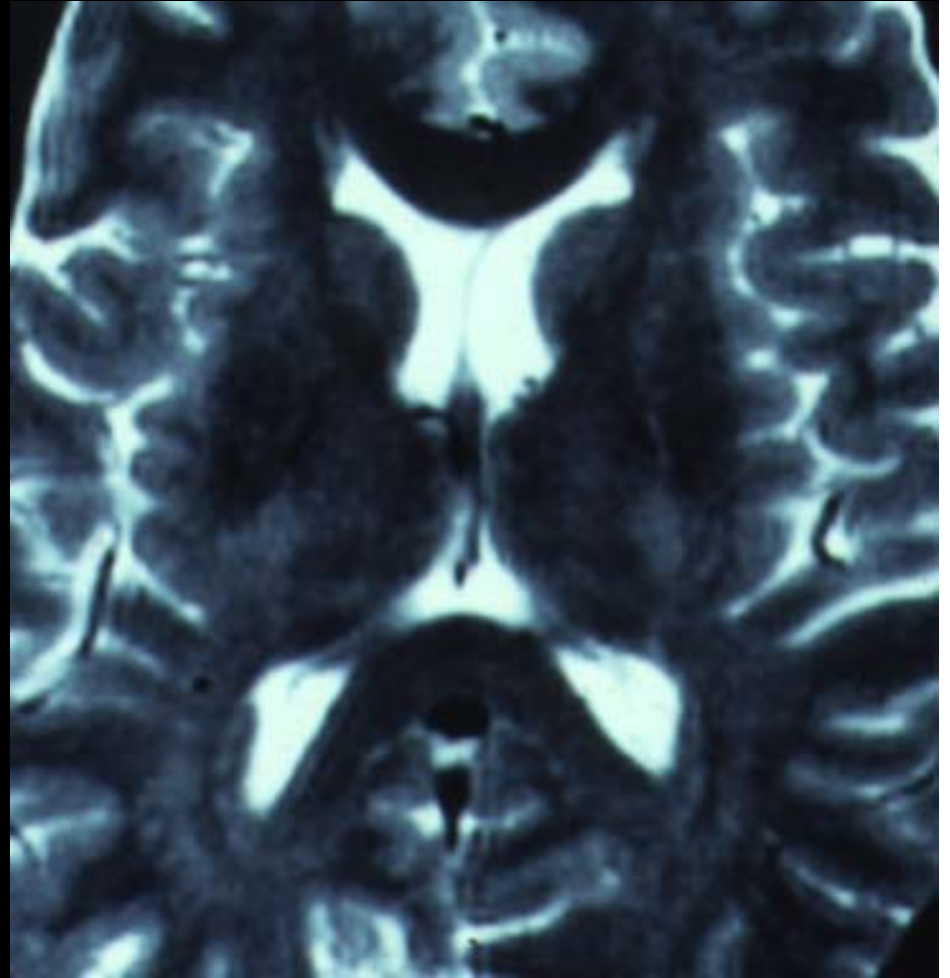
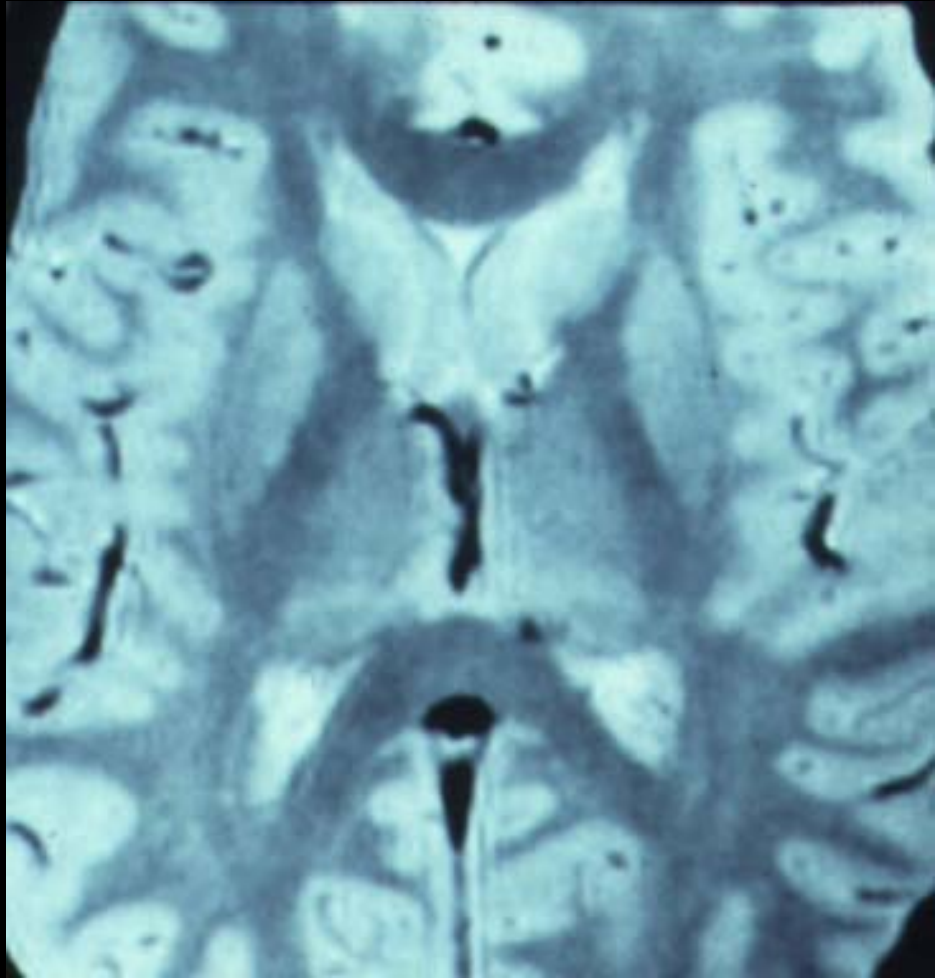
coronal
IE

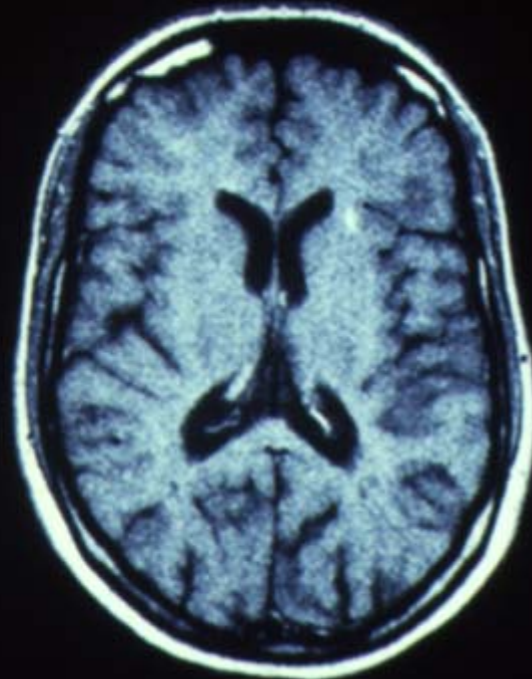
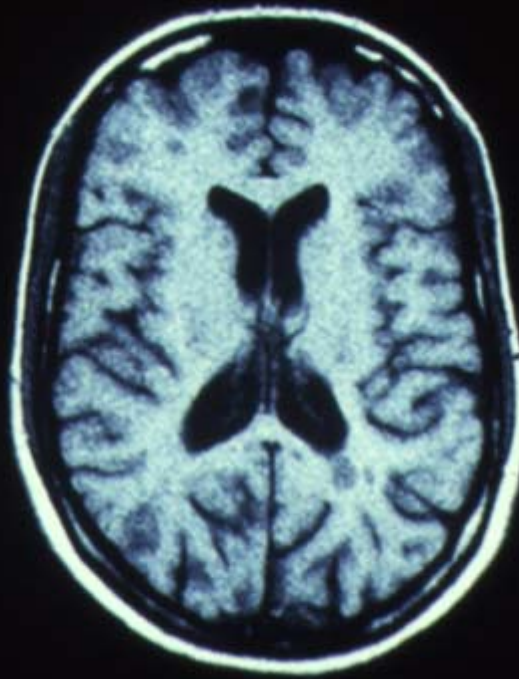
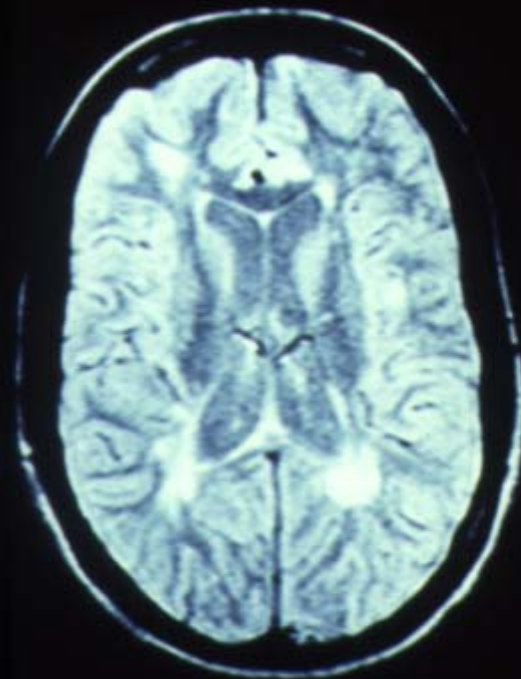
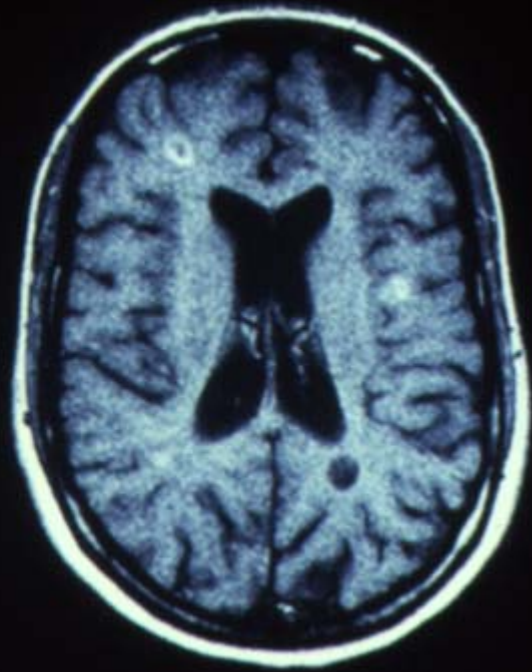
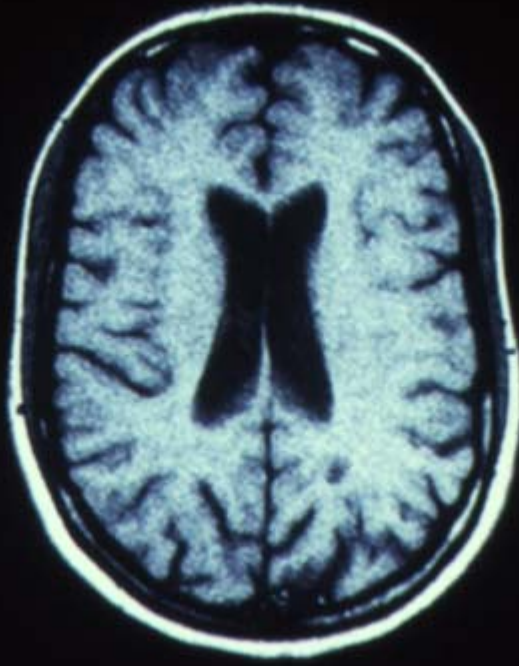
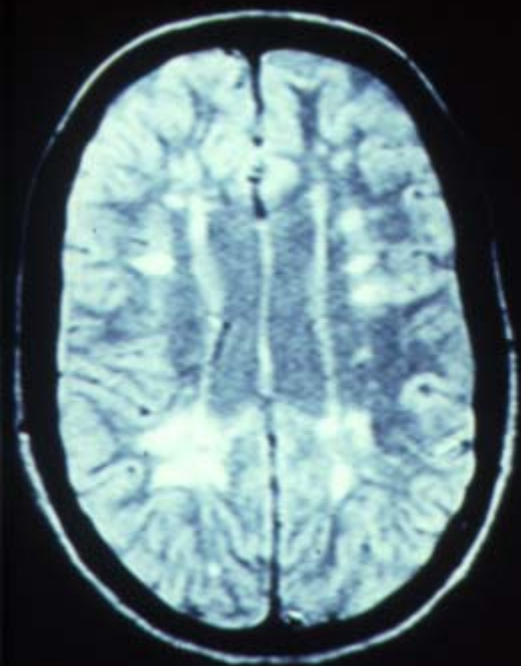


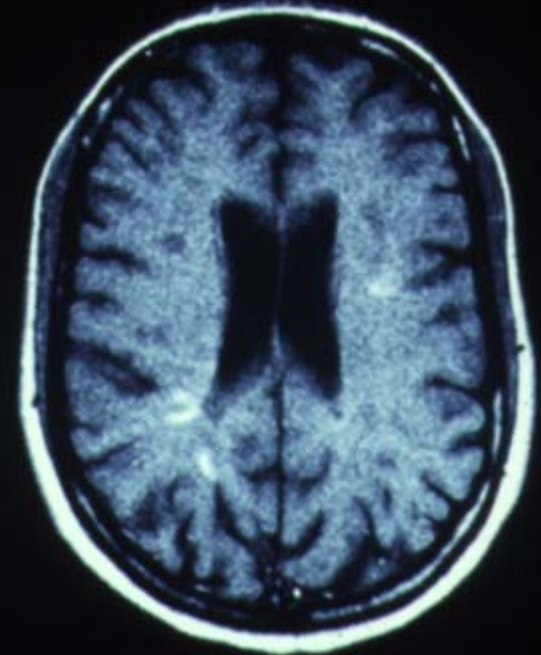
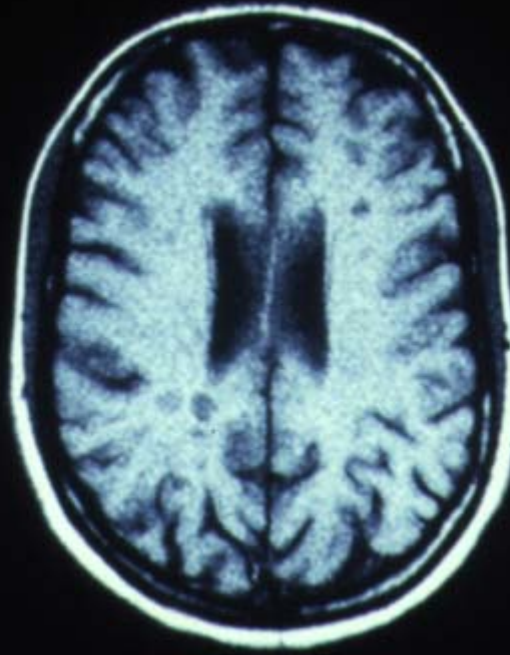
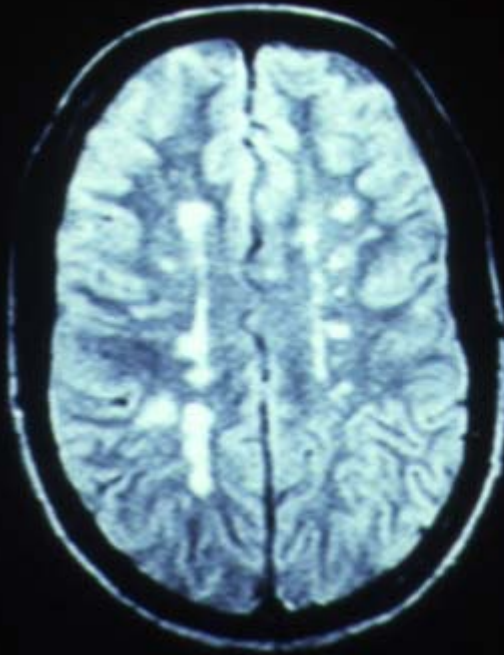
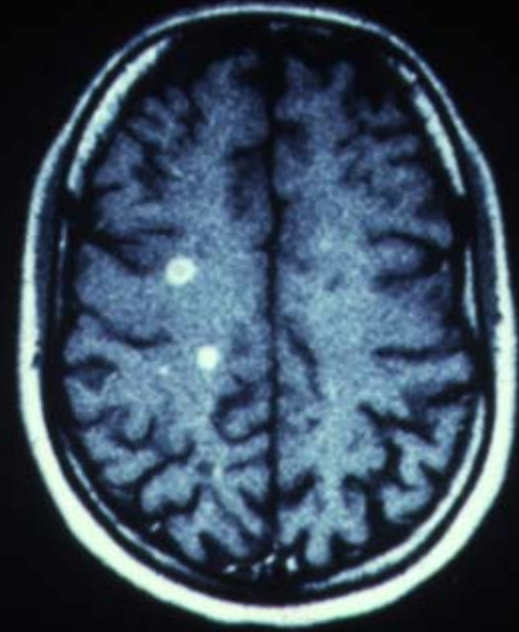
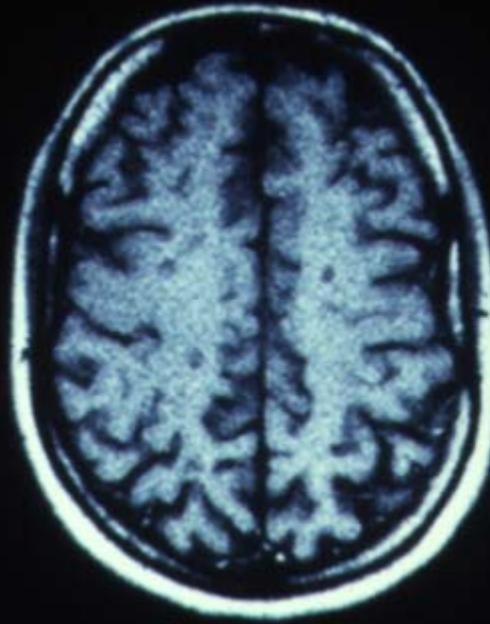
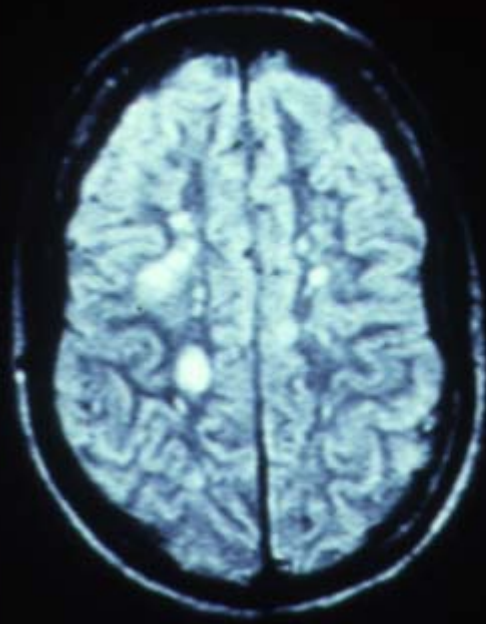
coronal IE_2

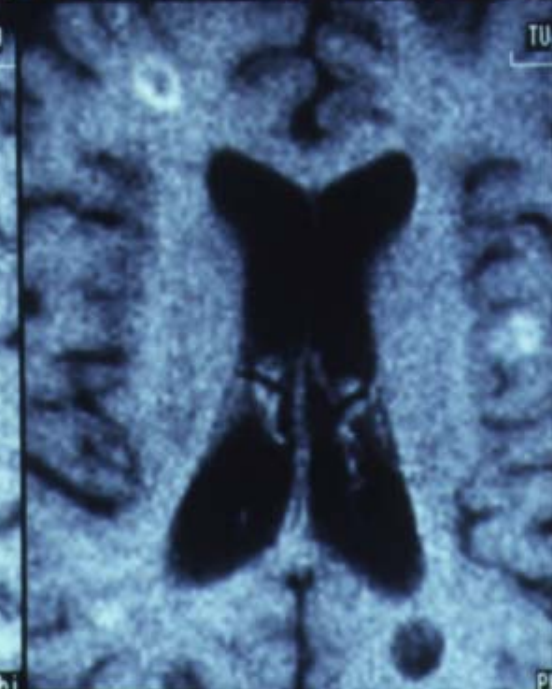
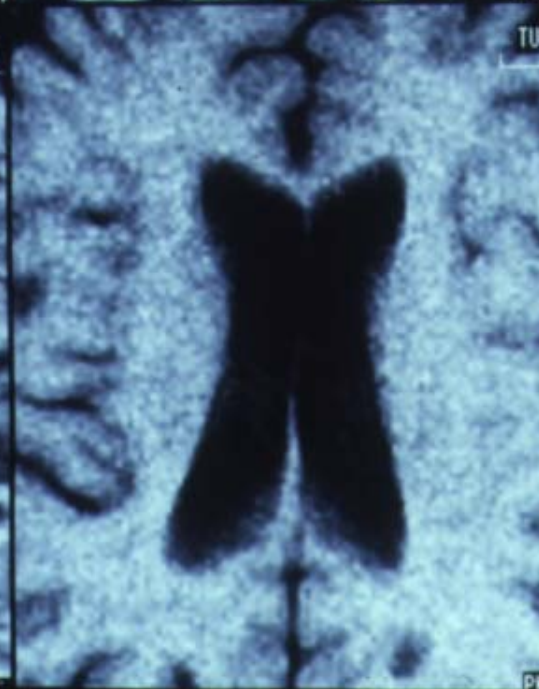
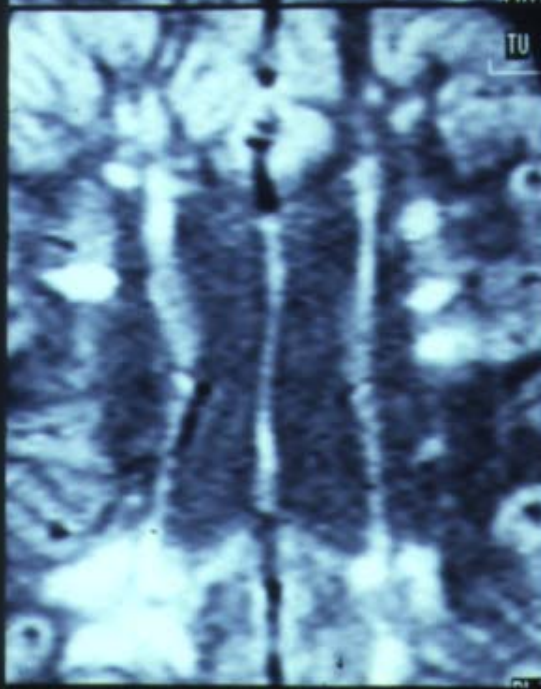
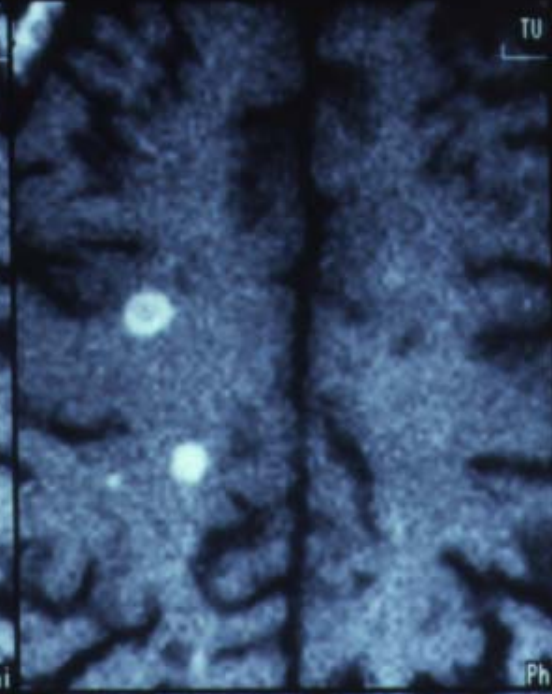
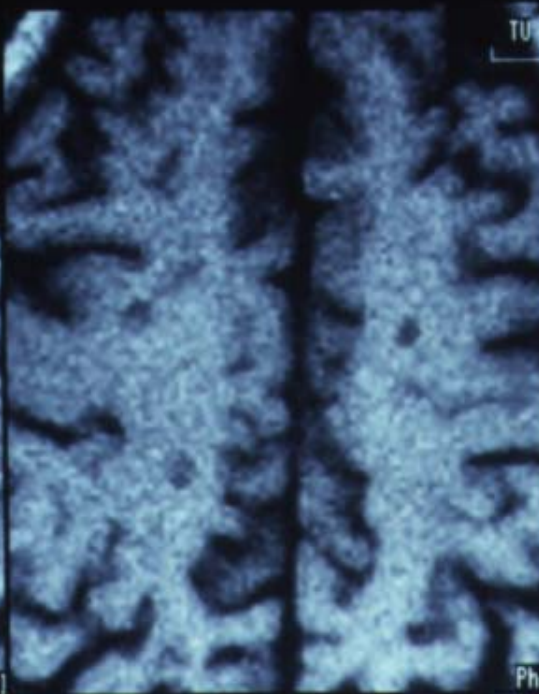
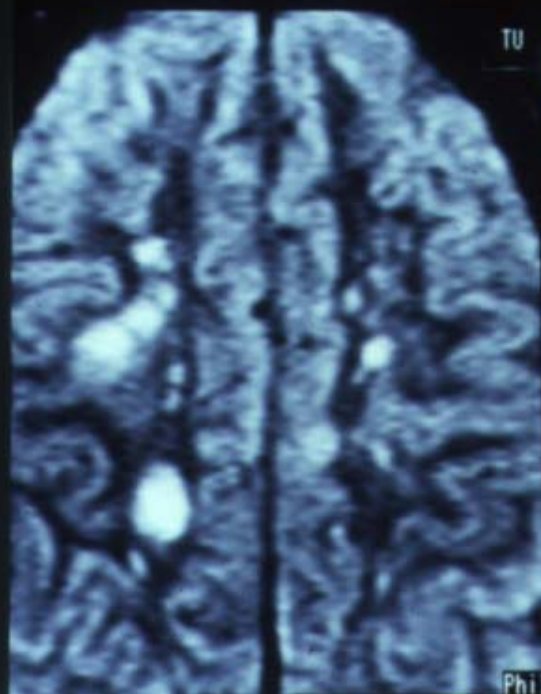


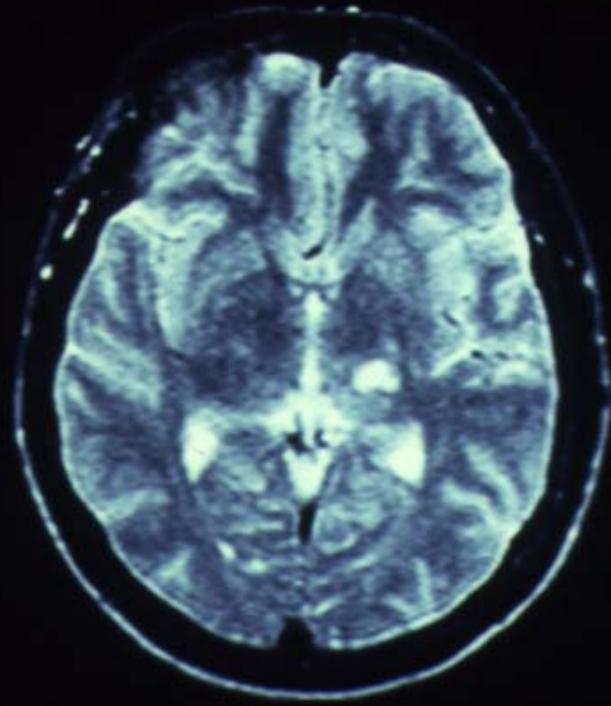
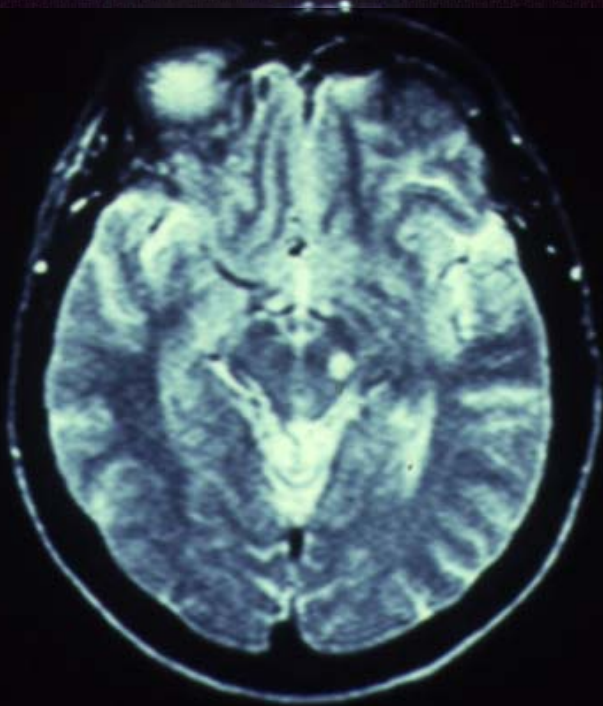
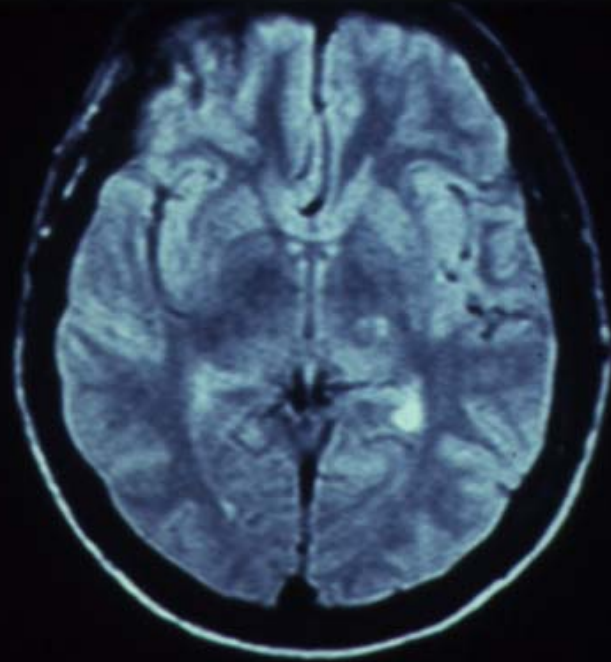
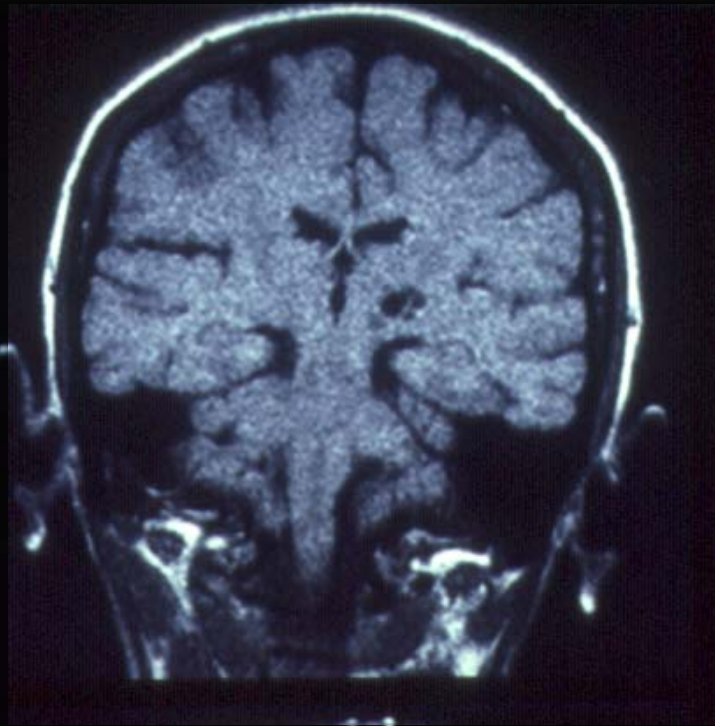


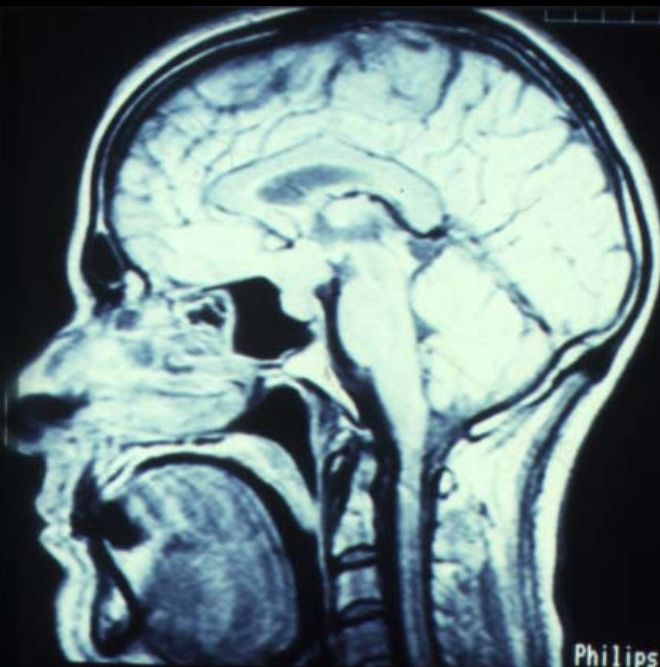



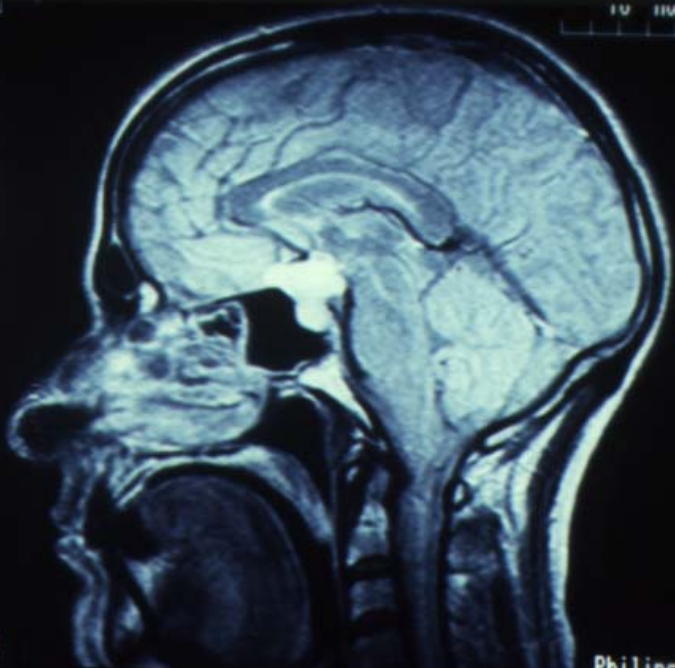




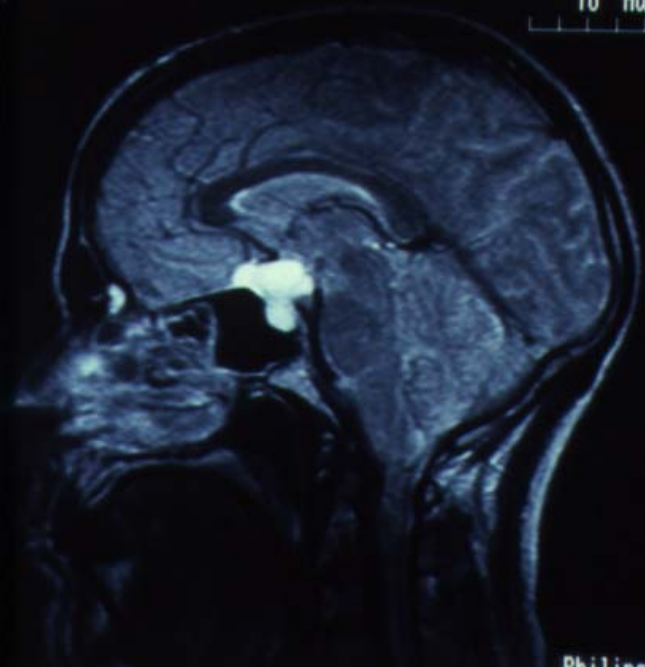




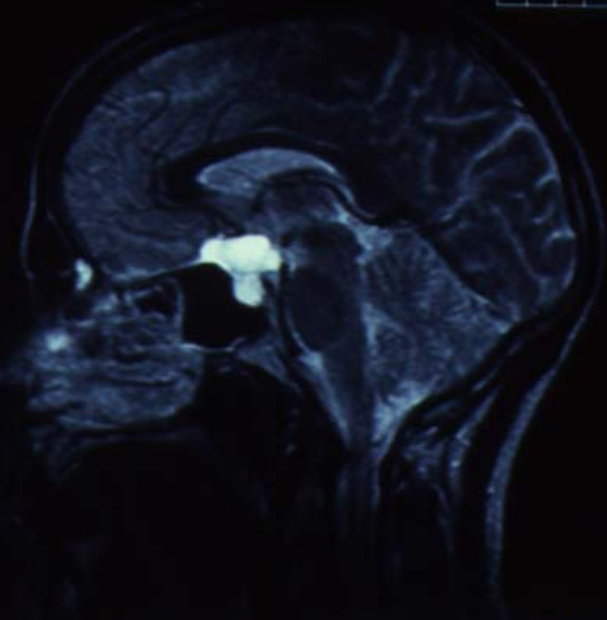
Philips 6
TU Muenc rg



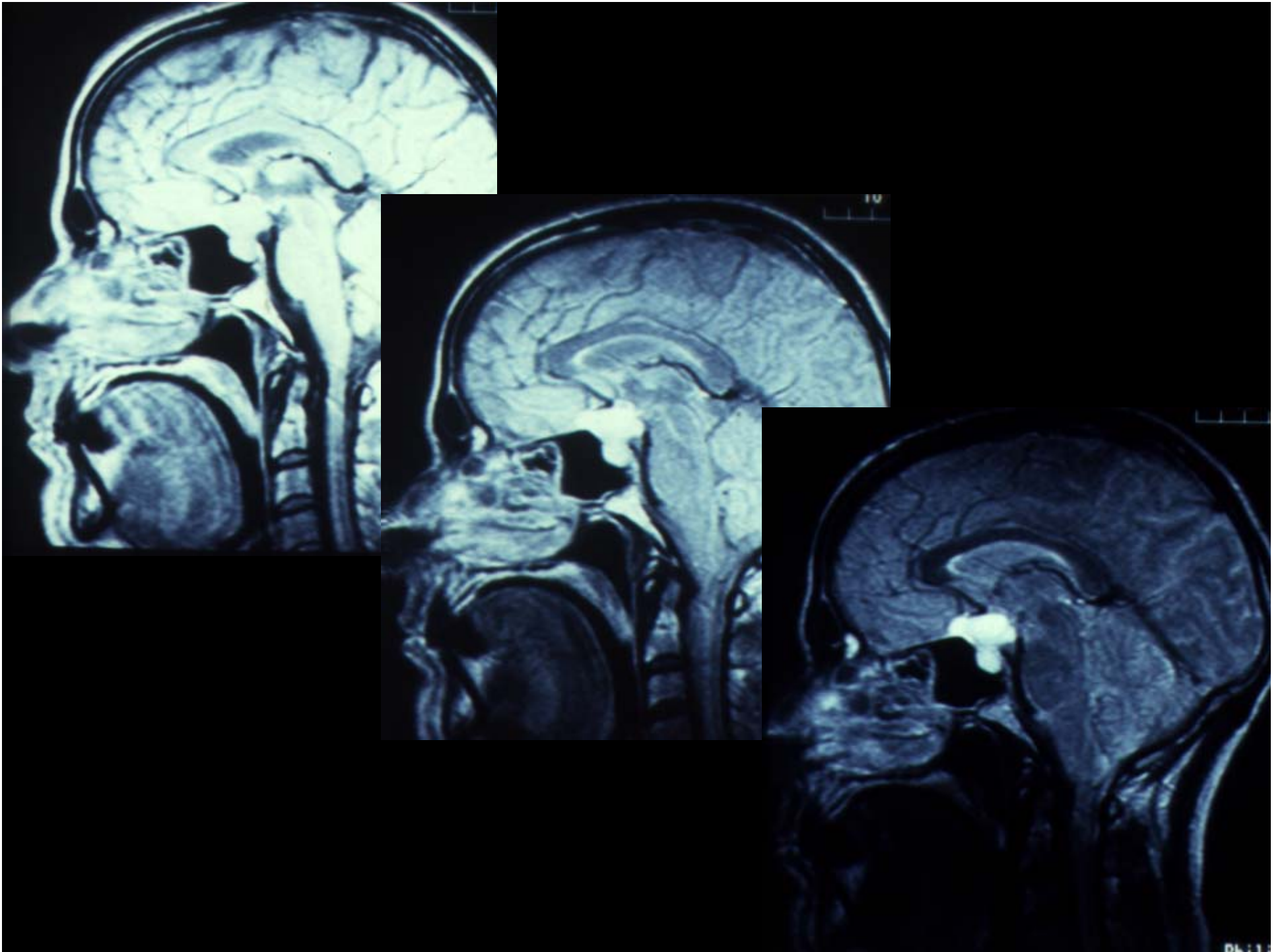
Philips
TU Muenc

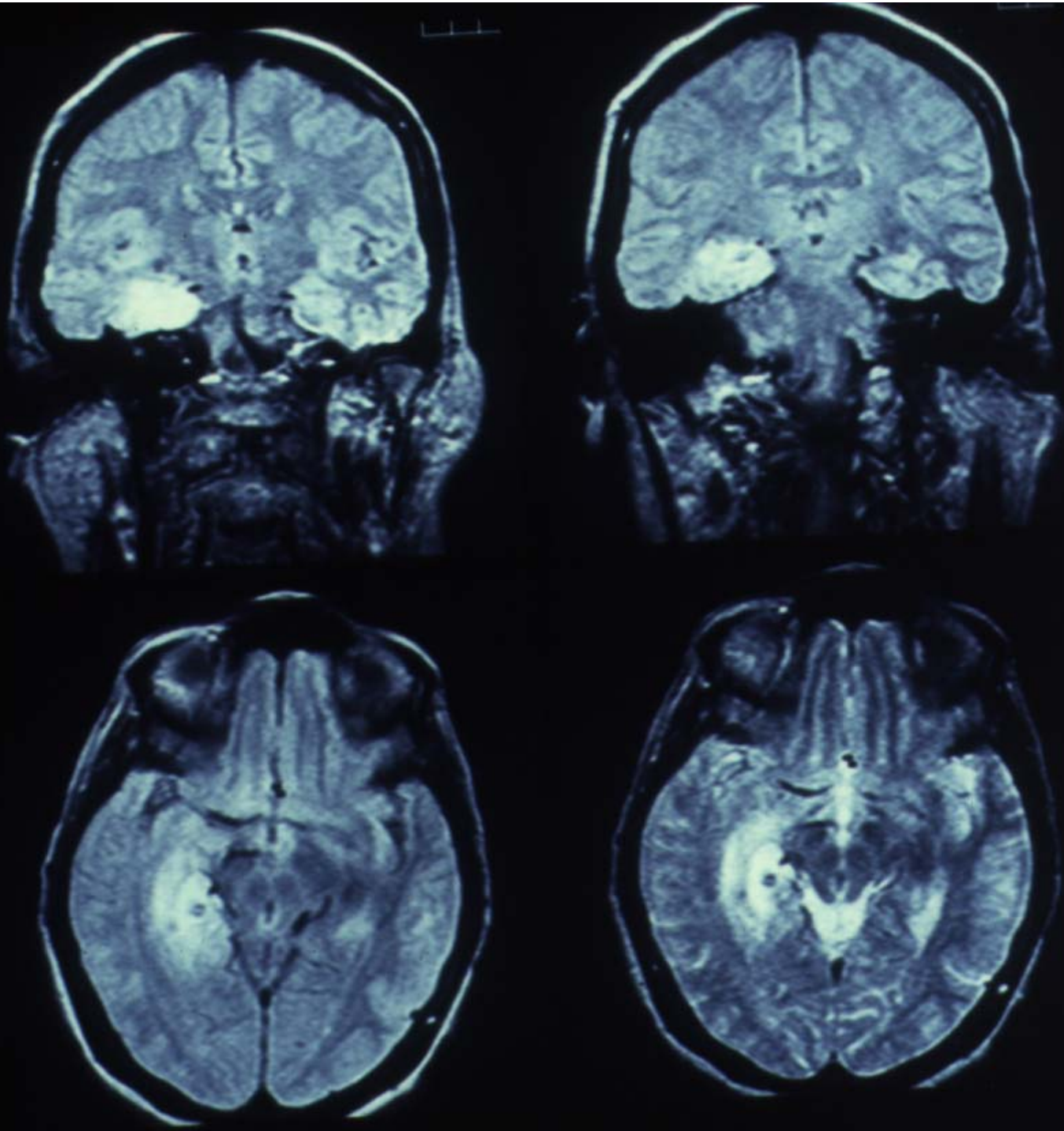


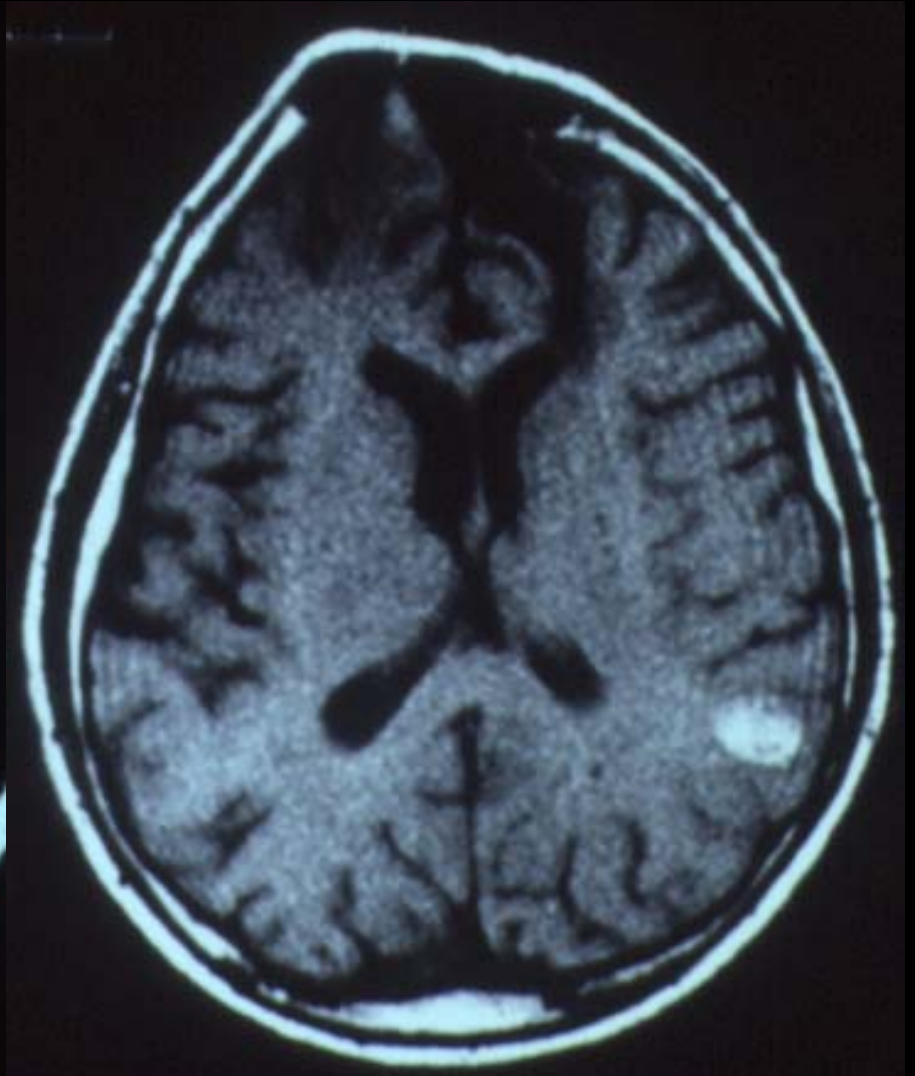
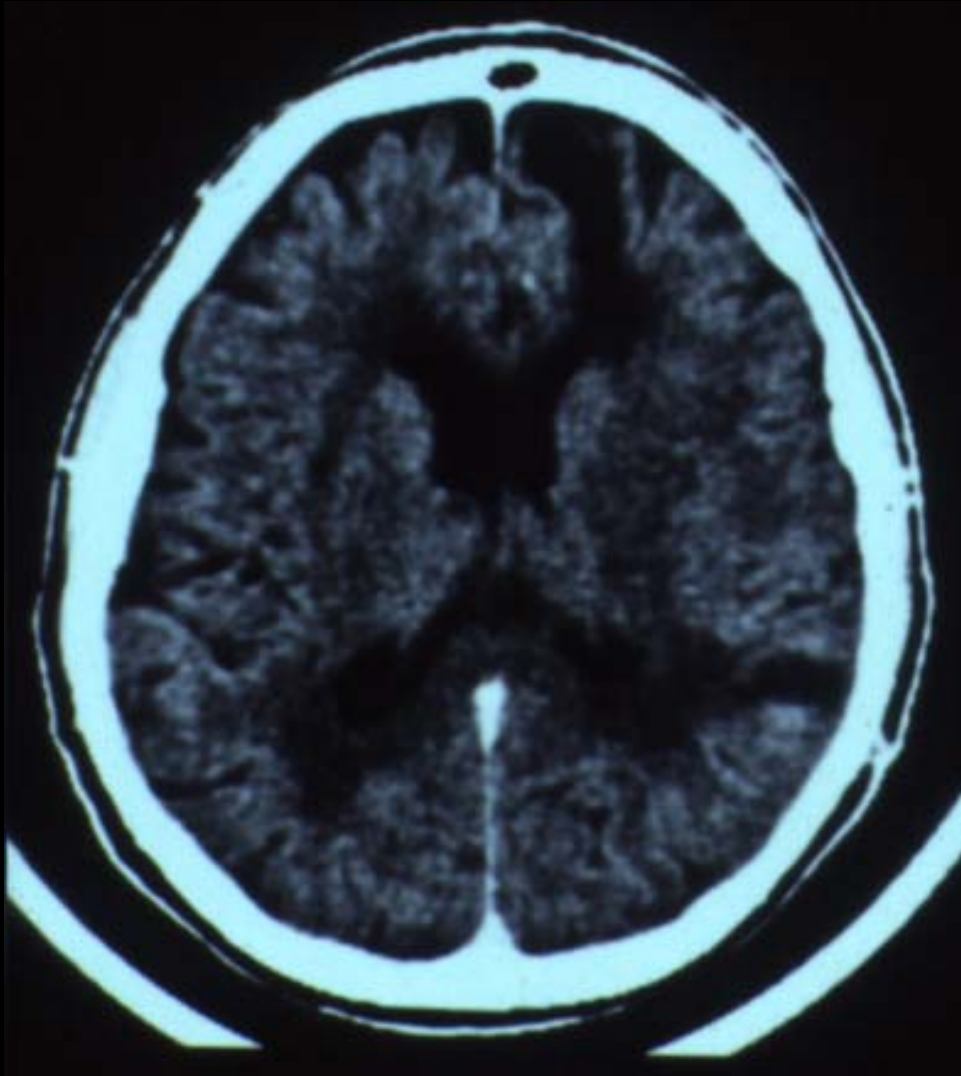
Philips 6

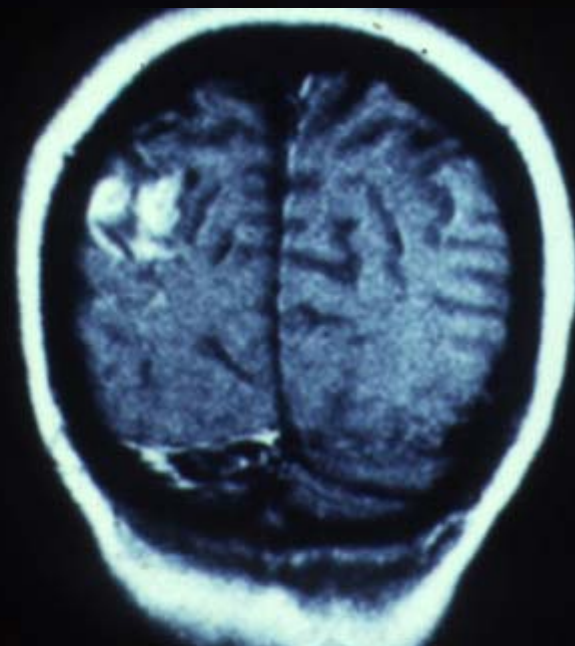
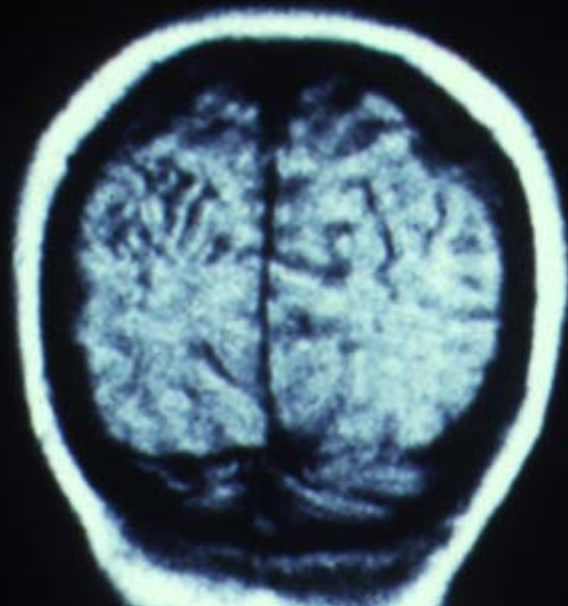
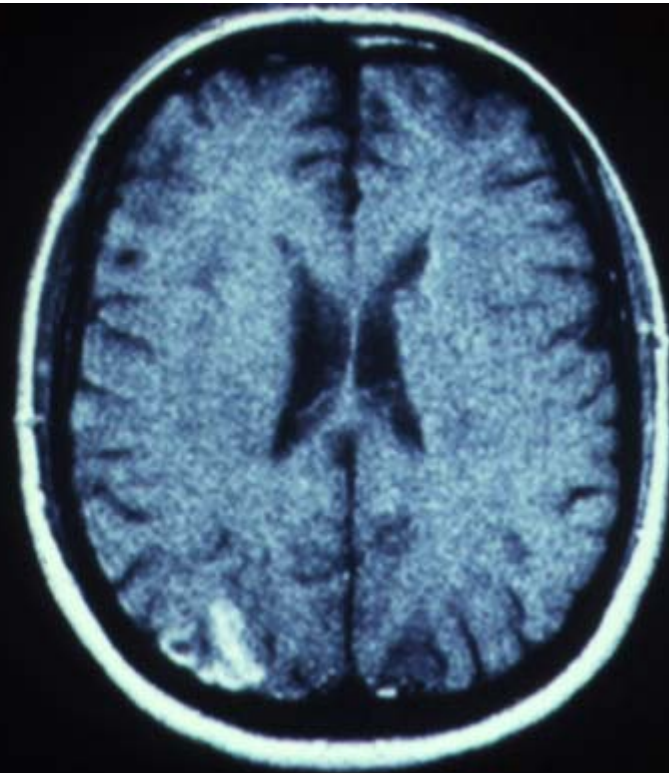
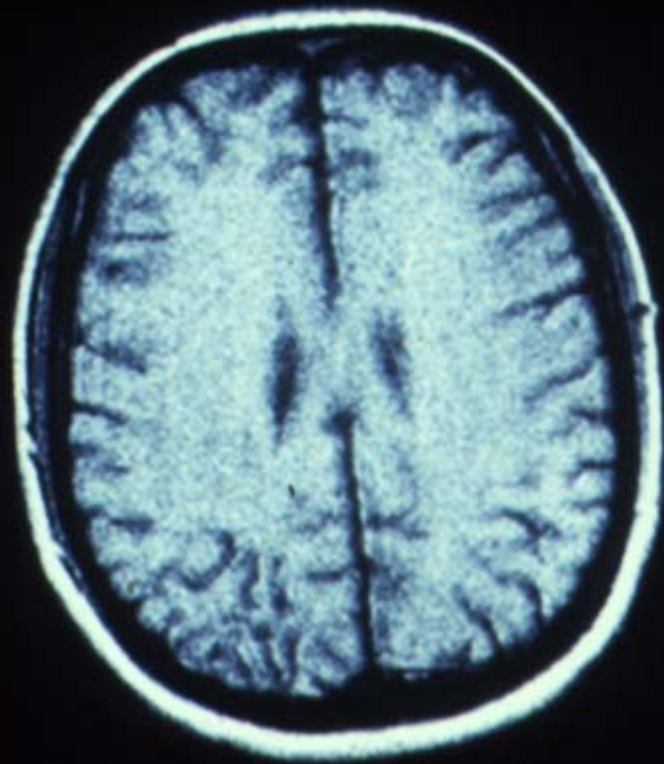


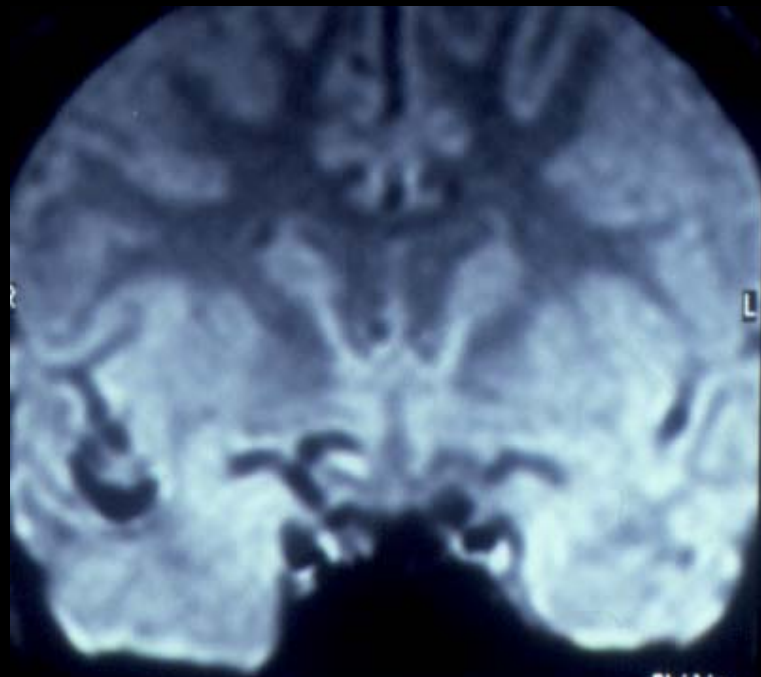
Philips 6



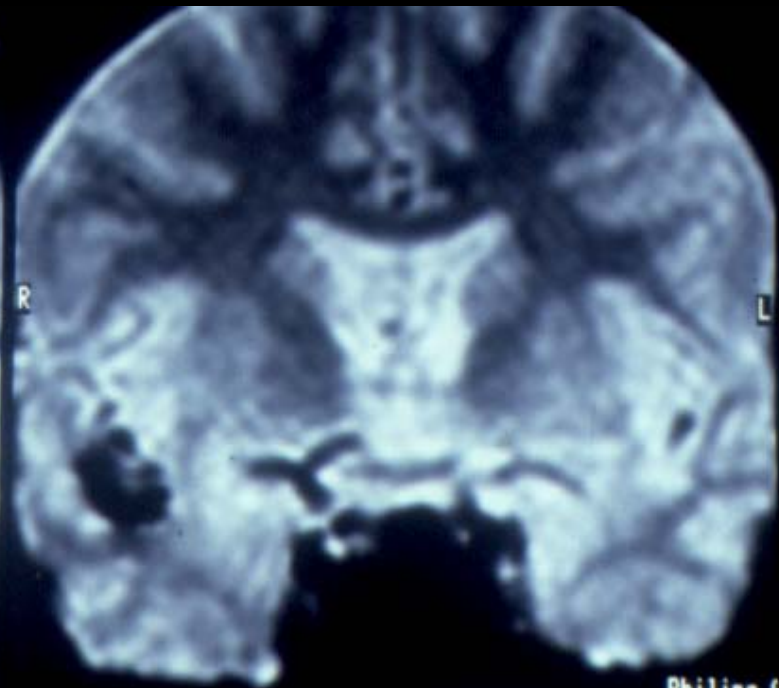




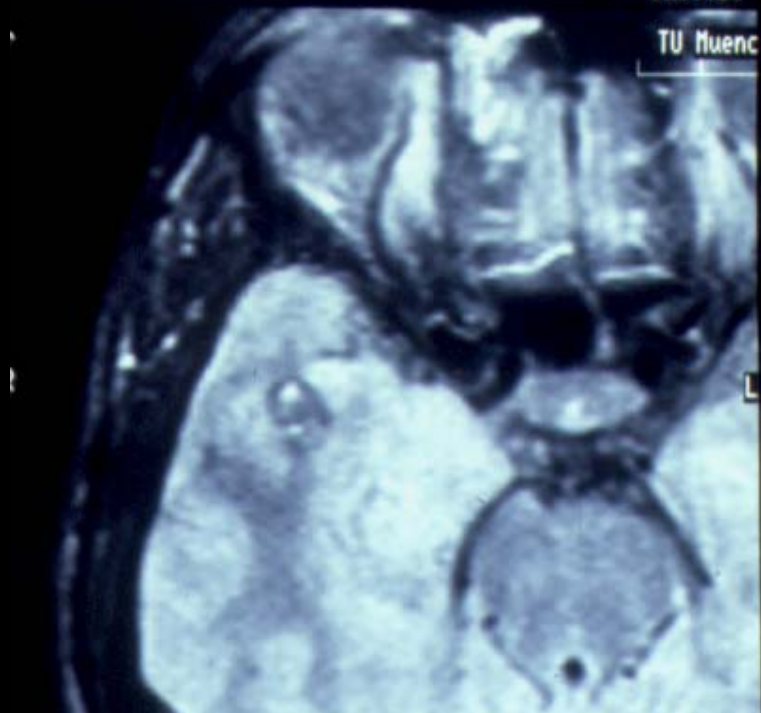




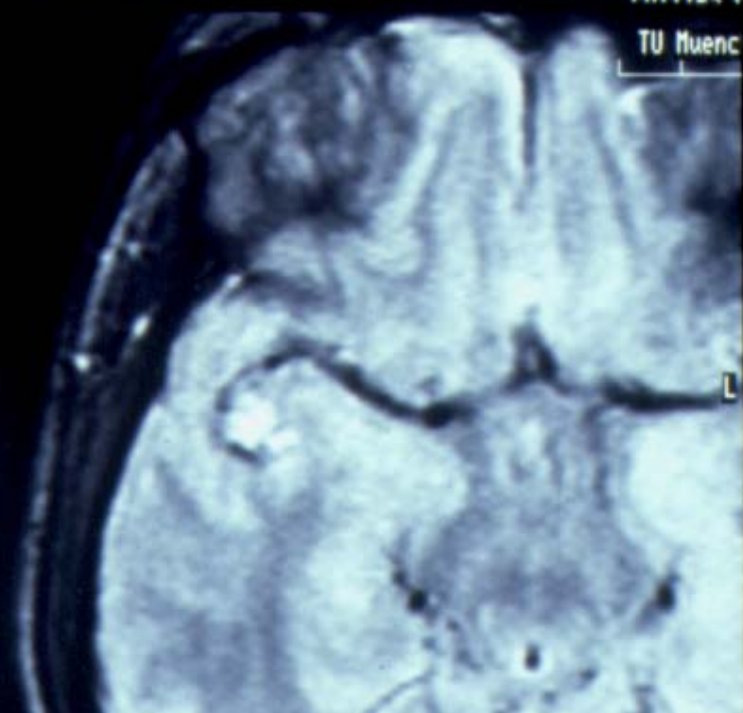
Philips
TU Muench 20



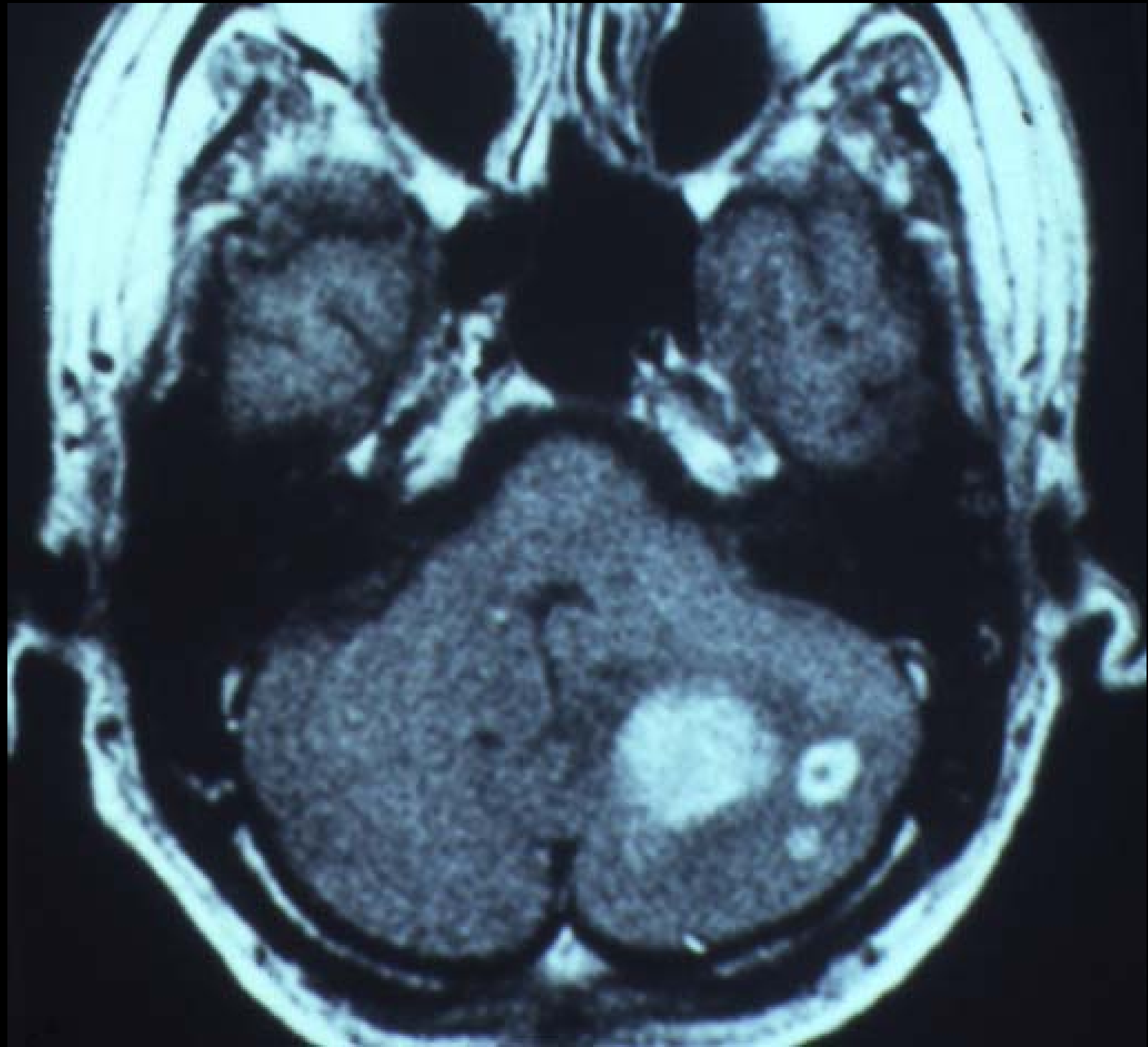
Philips
TU Muench

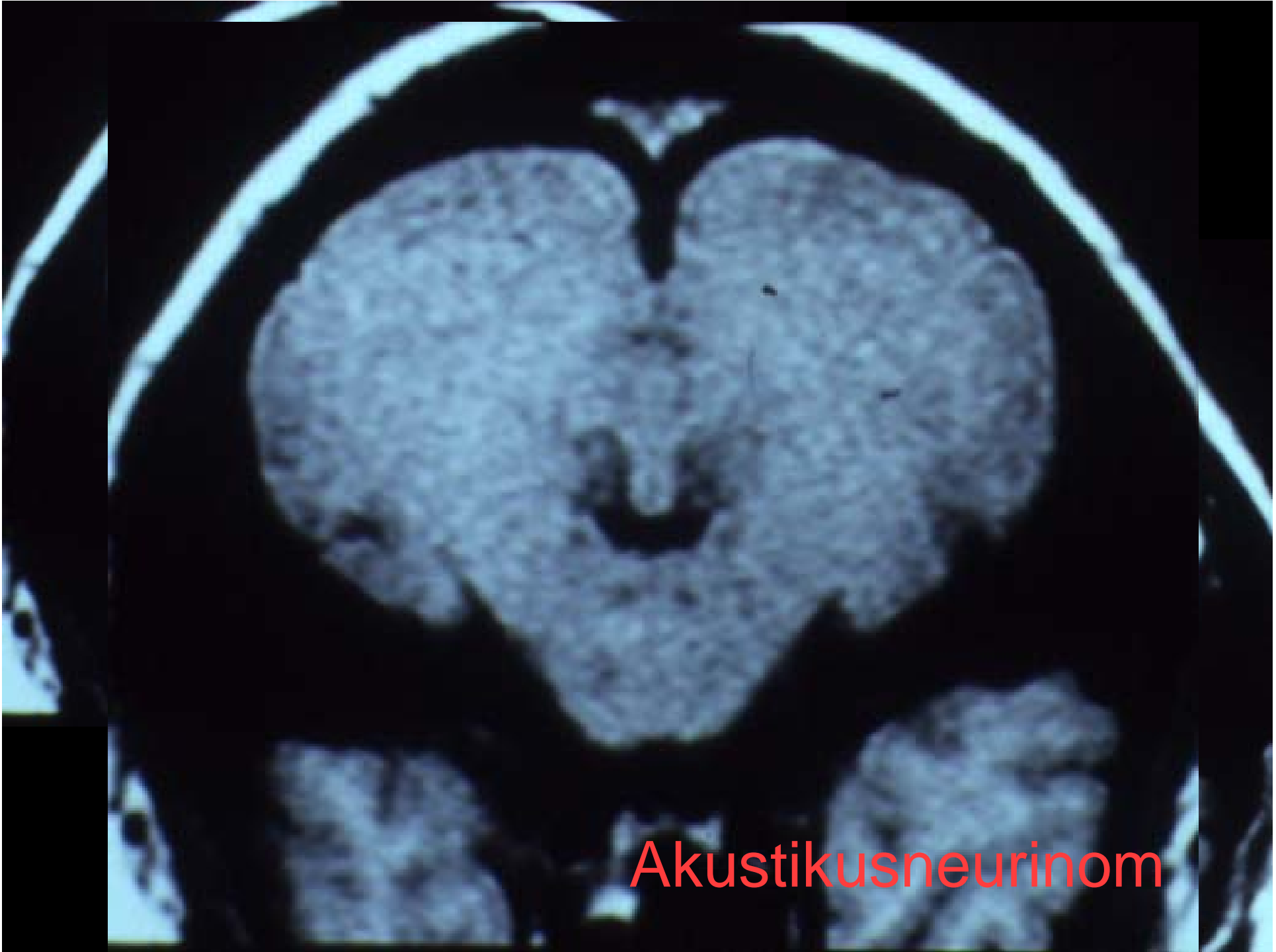


L R



L





Akustikusneurinom

